



**NCCN Clinical Practice Guidelines in Oncology (NCCN Guidelines®)**

# **Cervical Cancer**

Version 1.2017 – October 10, 2016

**NCCN.org**

**Continue**



\*Wui-Jin Koh, MD/Co-Chair §  
Fred Hutchinson Cancer Research  
Center/Seattle Cancer Care Alliance

\*Benjamin E. Greer, MD/Co-Chair Ω  
Fred Hutchinson Cancer Research  
Center/Seattle Cancer Care Alliance

\*Nadeem R. Abu-Rustum, MD Ω/Vice Chair  
Memorial Sloan Kettering Cancer Center

Susana M. Campos, MD, MPH, MS †  
Dana-Farber/Brigham and Women's  
Cancer Center

Kathleen R. Cho, MD ≠  
University of Michigan  
Comprehensive Cancer Center

Hye Sook Chon, MD Ω  
Moffitt Cancer Center

Christina Chu, MD Ω  
Fox Chase Cancer Center

David Cohn, MD Ω  
The Ohio State University Comprehensive  
Cancer Center - James Cancer Hospital  
and Solove Research Institute

Marta Ann Crispens, MD Ω  
Vanderbilt-Ingram Cancer Center

Don S. Dizon, MD †  
Massachusetts General Hospital  
Cancer Center

Oliver Dorigo, MD, PhD Ω  
Stanford Cancer Institute

**NCCN**  
Nicole McMillian, MS  
Jillian Scavone, PhD

[NCCN Guidelines Panel Disclosures](#)

Patricia J. Eifel, MD §  
The University of Texas  
MD Anderson Cancer Center

Christine M. Fisher, MD, MPH §  
University of Colorado Cancer Center

Peter Frederick, MD Ω  
Roswell Park Cancer Institute

David K. Gaffney, MD, PhD §  
Huntsman Cancer Institute  
at the University of Utah

Ernest Han, MD, PhD Ω  
City of Hope Comprehensive  
Cancer Center

Susan Higgins, MD §  
Yale Cancer Center/Smilow Cancer Hospital

Warner K. Huh, MD Ω  
University of Alabama at Birmingham  
Comprehensive Cancer Center

John R. Lurain, III, MD Ω  
Robert H. Lurie Comprehensive Cancer  
Center of Northwestern University

Andrea Mariani, MD Ω  
Mayo Clinic Cancer Center

David Mutch, MD Ω  
Siteman Cancer Center at Barnes-  
Jewish Hospital and Washington  
University School of Medicine

Christa Nagel, MD Ω  
Case Comprehensive Cancer Center/University  
Hospitals Seidman Cancer Center and Cleveland  
Clinic Taussig Cancer Institute

Larissa Nekhlyudov, MD, MPH  
Dana-Farber/Brigham and Women's Cancer Center

Amanda Nickles Fader, MD Ω  
The Sidney Kimmel Comprehensive  
Cancer Center at Johns Hopkins

Steven W. Remmenga, MD Ω  
Fred & Pamela Buffett Cancer Center

R. Kevin Reynolds, MD Ω  
University of Michigan  
Comprehensive Cancer Center

Todd Tillmanns, MD Ω  
St. Jude Children's Research Hospital/  
University of Tennessee Health Science Center

Stefanie Ueda, MD Ω  
UCSF Helen Diller Family  
Comprehensive Cancer Center

Fidel A. Valea, MD Ω  
Duke Cancer Institute

Emily Wyse  
Patient Advocate

Catheryn M. Yashar, MD §  
UC San Diego Moores Cancer Center

**Continue**

Ω Gynecologic oncology  
† Medical oncology  
§ Radiotherapy/Radiation oncology  
≠ Pathology  
\* Discussion Section Writing Committee

**Principles of Imaging\*****Nadeem R. Abu-Rustum, MD Ω/Lead**  
**Memorial Sloan Kettering Cancer Center****Hye Sook Chon, MD, MS Ω**  
**Moffitt Cancer Center****Christina Chu, MD Ω**  
**Fox Chase Cancer Center****Don S. Dizon, MD †**  
**Massachusetts General Hospital  
Cancer Center****Christine M. Fisher, MD, MPH §**  
**University of Colorado Cancer Center****David K. Gaffney, MD, PhD §**  
**Huntsman Cancer Institute  
at the University of Utah****Ernest Han, MD, PhD Ω**  
**City of Hope Comprehensive  
Cancer Center****Andrea Mariani, MD Ω**  
**Mayo Clinic Cancer Center****Larissa Nekhlyudov, MD, MPH**  
**Dana-Farber/Brigham and Women's  
Cancer Center****Fidel A. Valea, MD Ω**  
**Duke Cancer Institute**

\*NCCN gratefully acknowledges the following NCCN Imaging Panel member for their contributions during the development of the Principles of Imaging (CERV-A) in Version 1.2017 of the NCCN Guidelines for Vulvar Cancer:

Kristin Dittmar, MD ϕ  
The Ohio State University Comprehensive Cancer Center  
- James Cancer Hospital and Solove Research Institute

ϕ Diagnostic Radiology  
Ω Gynecologic oncology  
† Medical oncology  
§ Radiotherapy/Radiation oncology

**[NCCN Guidelines Panel Disclosures](#)**



[NCCN Cervical Cancer Panel Members](#)

[NCCN Cervical Cancer Sub-Committees](#)

[Summary of the Guidelines Updates](#)

[Clinical Stage \(CERV-1\)](#)

[Stage IA1 \(no LVSI\), Stage IA1 \(with LVSI\) and Stage IA2, Stage IB1 \(Fertility Sparing\) \(CERV-2\)](#)

[Stage IA1 \(no LVSI\), Stage IA1 \(with LVSI\) and Stage IA2 \(Non-Fertility Sparing\) \(CERV-3\)](#)

[Stage IB1 and Stage IIA1 \(Non-Fertility Sparing\) \(CERV-4\)](#)

[Stage IB2 and Stage IIA2 \(Non-Fertility Sparing\) \(CERV-4\)](#)

[Stage IB2, Stage IIA2, and Stages IIB, IIIA, IIIB, IVA \(CERV-6\)](#)

[Incidental Finding of Invasive Cancer After Simple Hysterectomy \(CERV-9\)](#)

[Surveillance \(CERV-10\)](#)

[Local/Regional Recurrence \(CERV-11\)](#)

[Distant Metastases \(CERV-12\)](#)

[Principles of Imaging \(CERV-A\)](#)

[Principles of Evaluation and Surgical Staging \(CERV-B\)](#)

[Principles of Radiation Therapy for Cervical Cancer \(CERV-C\)](#)

[Sedlis Criteria For External Pelvic Radiation After Radical Hysterectomy In Node-Negative,](#)

[Margin-Negative, Parametria-Negative Cases \(CERV-D\)](#)

[Chemotherapy Regimens for Recurrent or Metastatic Cervical Cancer \(CERV-E\)](#)

[Staging \(ST-1\)](#)

**The NCCN Guidelines for Cervical Cancer include the management of squamous cell carcinoma, adenosquamous carcinoma, and adenocarcinoma of the cervix.**

**Clinical Trials:** NCCN believes that the best management for any cancer patient is in a clinical trial. Participation in clinical trials is especially encouraged.

To find clinical trials online at NCCN Member Institutions, [click here: nccn.org/clinical\\_trials/physician.html](#).

**NCCN Categories of Evidence and Consensus:** All recommendations are category 2A unless otherwise specified.

See [NCCN Categories of Evidence and Consensus](#).

The NCCN Guidelines® are a statement of evidence and consensus of the authors regarding their views of currently accepted approaches to treatment. Any clinician seeking to apply or consult the NCCN Guidelines is expected to use independent medical judgment in the context of individual clinical circumstances to determine any patient's care or treatment. The National Comprehensive Cancer Network® (NCCN®) makes no representations or warranties of any kind regarding their content, use or application and disclaims any responsibility for their application or use in any way. The NCCN Guidelines are copyrighted by National Comprehensive Cancer Network®. All rights reserved. The NCCN Guidelines and the illustrations herein may not be reproduced in any form without the express written permission of NCCN. ©2016.

Updates in Version 1.2017 of the NCCN Guidelines for Cervical Cancer from Version 1.2016 include:

### Global changes

- A new section for “Principles of Imaging” that includes recommendations for “Initial Workup” and “Follow-up/Surveillance” was added to the Guidelines to clarify recommended modalities wherever imaging is mentioned. Recommendations for specific imaging modalities (ie, CT, PET, MRI) were removed from the algorithms and described in greater detail in the new imaging section ([CERV-A](#)).
- Footnote b was revised: ~~“CT and MRI performed with contrast throughout the guidelines unless contraindicated. Contrast not required for screening chest CT. See Principles of Imaging (CERV-A).”~~
- The recommendation “Consider sentinel lymph node (SLN) mapping” changed from category 2B to category 2A wherever it is mentioned throughout the Guidelines (including footnotes).
- “RT” was clarified as “EBRT” throughout the Guidelines.
- The Discussion was updated to reflect the changes in the algorithm ([MS-1](#)).

### CERV-1

Workup; Sixth bullet revised: “Imaging (optional for  $\leq$  stage IB1).” The modalities “Chest x-ray, CT, or PET/CT scan, MRI as indicated,” were deleted from this page and clarified in the new Principles of Imaging section ([CERV-A](#)).

### CERV-2

- Footnote “e” revised: “No data to support a fertility-sparing approach in small neuroendocrine tumors, ~~or minimal deviation adenocarcinoma (also known as adenoma malignum) gastric type adenocarcinoma, or adenoma malignum (also known as minimal deviation adenocarcinoma).~~ Total hysterectomy...”
- Footnote “f” revised: “Cold knife conization (CKC) is the preferred method of diagnostic excision, but loop electrosurgical excision procedure (LEEP) is acceptable, provided adequate margins and proper orientation are obtained. *Endocervical curettage (ECC) may be added as clinically indicated.*”
- Footnote “i” revised: “For SLN mapping (category 2B), the best detection rates and mapping results are in tumors <2 cm.”

### CERV-3

- Primary Treatment (Non-Fertility Sparing)
  - ▶ Stage 1A (no LVSI); Cone biopsy; Positive margins for dysplasia or carcinoma: “Consider repeat cone biopsy to better evaluate depth of invasion” moved above “Extracapsular or modified radical hysterectomy...”

### CERV-4

- Clinical Stage: Language revised, “Stage IB2 and Stage IIA2 ([also see CERV-6](#) for ~~alternative~~ **additional** recommendations for these **non-primary surgery patients**)”

### CERV 5

- After “Para-aortic lymph node positive by surgical staging” revised:
  - ▶ ~~“Chest CT or PET-CT scan Imaging workup for metastatic disease.”~~
  - ▶ Recommendation revised: “~~Systemic therapy~~ **Chemotherapy**  $\pm$  individualized EBRT.” (Also for CERV-7 and CERV-8)

### CERV-7

- Footnote “s” revised: “Consider postoperative imaging (*abdominal/ pelvic CT or MRI with contrast*) to confirm the adequacy of node removal.”

### CERV-8

- After “Para-aortic lymph node positive by surgical staging” revised “Further radiologic workup *for metastatic disease* as clinically indicated.”

### CERV-9

- Incidental Finding of Invasive Cancer After Simple Hysterectomy
  - ▶ Language revised, “ $\geq$  Stage IA1 with LVSI ~~or  $\geq$  Stage IA2.~~”
    - ◇ Second column; Bottom pathway: Revised fourth bullet: “Imaging (optional for  $\leq$  stage IB1).” The sub-bulleted modalities “Chest x-ray, CT, or PET/CT scan, MRI as indicated,” were deleted from this page and clarified in the new *Principles of Imaging* section ([CERV-A](#)).
    - ◇ Negative margins; negative imaging: Recommendation revised, “~~Complete parametrectomy + upper vaginectomy~~ **Complete parametrectomy/upper vaginectomy** + pelvic lymph node dissection  $\pm$  para-aortic lymph node sampling (*category 2B for para-aortic lymph node sampling*).”

### CERV-10

#### • Surveillance

- ▶ Third bullet revised: “Imaging (~~chest radiography, CT, PET, PET/CT, MRI~~) as indicated based on symptoms or examination findings suspicious for recurrence”
- ▶ Fifth bullet revised: “Patient education regarding symptoms of potential recurrence, periodic self-examinations, lifestyle, obesity, exercise, *sexual health (including vaginal dilator use and lubricants/moisturizers)*, smoking cessation, nutrition counseling, *potential long-term and late effects of treatment...*”
- ▶ Bullet deleted: “Patient education regarding sexual health, vaginal dilator use, and vaginal lubricants/moisturizers (eg, estrogen creams).”
- Footnote “w” revised: “~~A single PET/CT scan performed at 3–6 months after chemoradiation for locally advanced cervical cancer can be used to suggest early or asymptomatic persistence/recurrence. Other imaging studies (such as chest x-ray, CT scan, MRI, and subsequent PET/CT) may also be used to assess or follow recurrence when clinically indicated but are not recommended for routine surveillance. (See Discussion).~~ Recurrences should be proven by biopsy before proceeding to treatment planning.”

### CERV-11

#### • Local/regional recurrence

- ▶ “No prior RT...” pathway; Therapy for Relapse: “Tumor-directed RT + platinum-based chemotherapy ± brachytherapy” changed to “~~Tumor-directed~~ *Individualized EBRT ± platinum-based* chemotherapy ± brachytherapy.”
- ▶ “Prior RT” pathway: Revised, “~~Tumor-directed Individualized EBRT ±~~ chemotherapy”

### CERV-12

#### • Distant Metastases; Amenable to local treatment; Therapy for Relapse: Recommendations revised,

- ▶ Local treatment: “Resection ± *Individualized EBRT* or Local ablative therapies ± *Individualized EBRT* or *Individualized EBRT ± concurrent chemotherapy*”
- ▶ “~~May Consider~~ *systemic* adjuvant chemotherapy”

### CERV-C Principles of Radiation Therapy

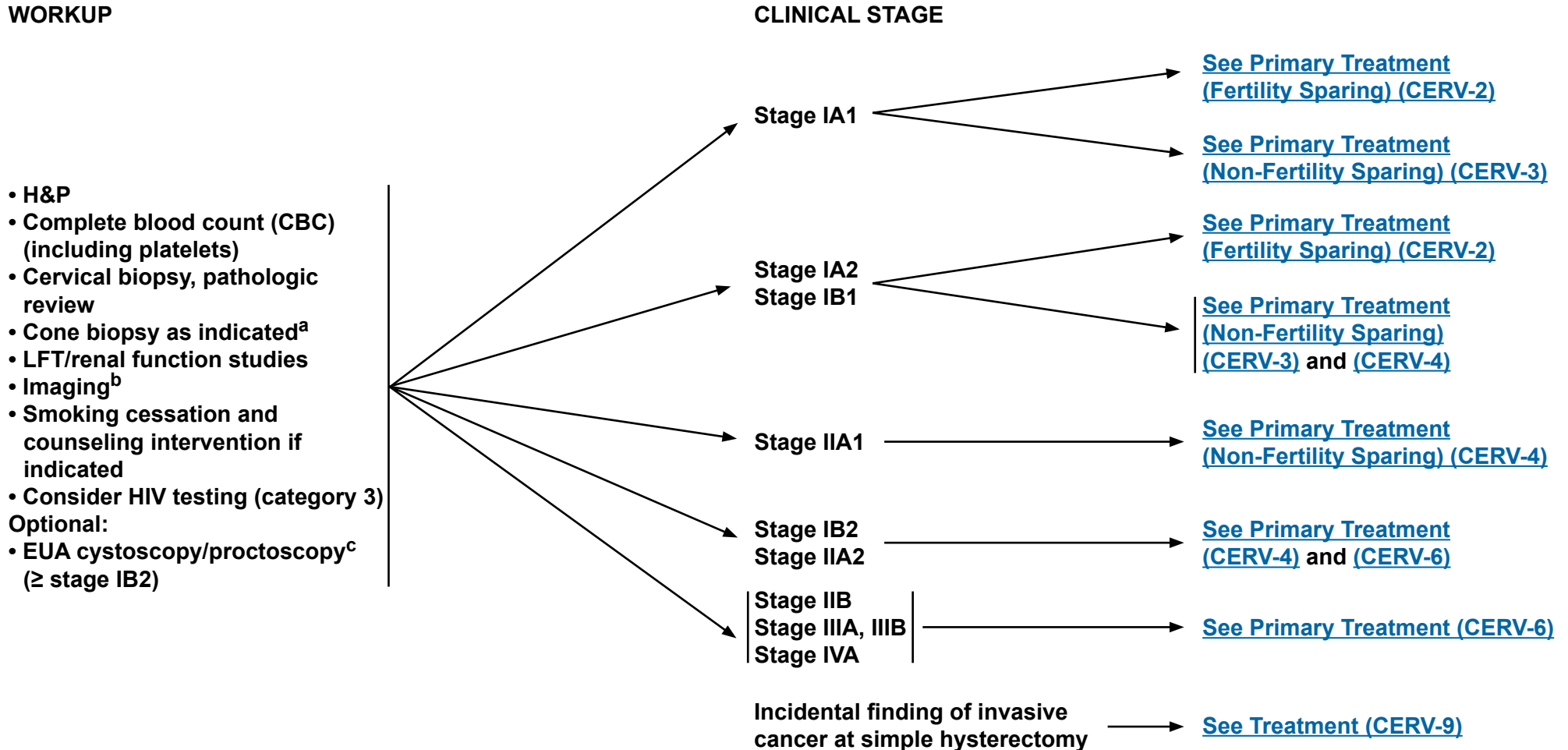
#### Page 1 of 5 External Beam Radiation Therapy (EBRT)

- Fourth bullet revised, “Intensity-modulated radiation therapy (IMRT) and similar highly conformal methods of dose delivery may be helpful in minimizing the dose to the bowel and other critical structures in the *IMRT* post-hysterectomy setting...”
- New bullet added “*Stereotactic body radiotherapy (SBRT) is an approach that allows delivery of very high doses of focused external beam radiation in 1–5 fractions and may be applied to isolated metastatic sites.*”

#### Page 5 of 5 References

#### • New references added:

- ▶ Klopp, AH, Yeung AR, Deshmukh S, et al.. *A Phase III Randomized Trial Comparing Patient-Reported Toxicity and Quality of Life (QOL) During Pelvic Intensity Modulated Radiation Therapy as Compared to Conventional Radiation Therapy. Int J Radiat Oncol Biol Phys* 2016;96:S3.
- ▶ Choi CW, Cho CK, Yoo SY, et al. *Image-guided stereotactic body radiation therapy in patients with isolated para-aortic lymph node metastases from uterine cervical and corpus cancer. Int J Radiat Oncol Biol Phys* 2009;74:147–153.
- ▶ Higginson DS, Morris DE, Jones EL, et al. *Stereotactic body radiotherapy (SBRT): Technological innovation and application in gynecologic oncology. Gynecol Oncol* 2011;120:404–412.



All staging in guideline is based on updated 2009 FIGO staging. [\(See ST-1\)](#)

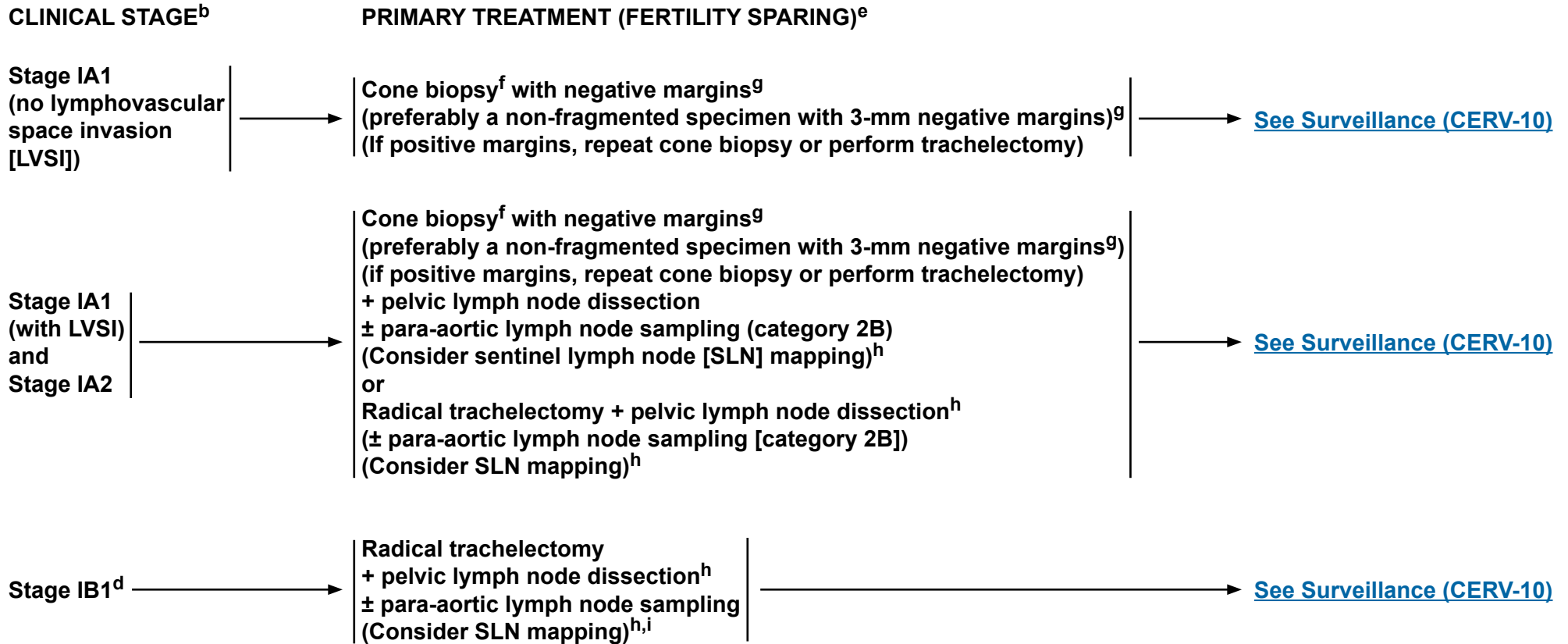
<sup>a</sup>See [Discussion](#) for indications for cone biopsy.

<sup>b</sup>See [Principles of Imaging \(CERV-A\)](#).

<sup>c</sup>For suspicion of bladder/bowel involvement, cystoscopy/proctoscopy with biopsy is required.

**Note:** All recommendations are category 2A unless otherwise indicated.  
**Clinical Trials:** NCCN believes that the best management of any patient with cancer is in a clinical trial. Participation in clinical trials is especially encouraged.





<sup>b</sup>[See Principles of Imaging \(CERV-A\).](#)

<sup>d</sup>Fertility-sparing surgery for stage IB1 has been most validated for tumors ≤2 cm. Small cell neuroendocrine histology and adenoma malignum are not considered suitable tumors for this procedure.

<sup>e</sup>No data to support a fertility-sparing approach in small neuroendocrine tumors, gastric type adenocarcinoma, or adenoma malignum (also known as minimal deviation adenocarcinoma). Total hysterectomy after completion of childbearing is at the patient's and surgeon's discretion, but is strongly advised in women with continued abnormal pap smears or chronic persistent HPV infection.

<sup>f</sup>Cold knife conization (CKC) is the preferred method of diagnostic excision, but loop electrosurgical excision procedure (LEEP) is acceptable, provided adequate margins and proper orientation are obtained. Endocervical curettage (ECC) may be added as clinically indicated.

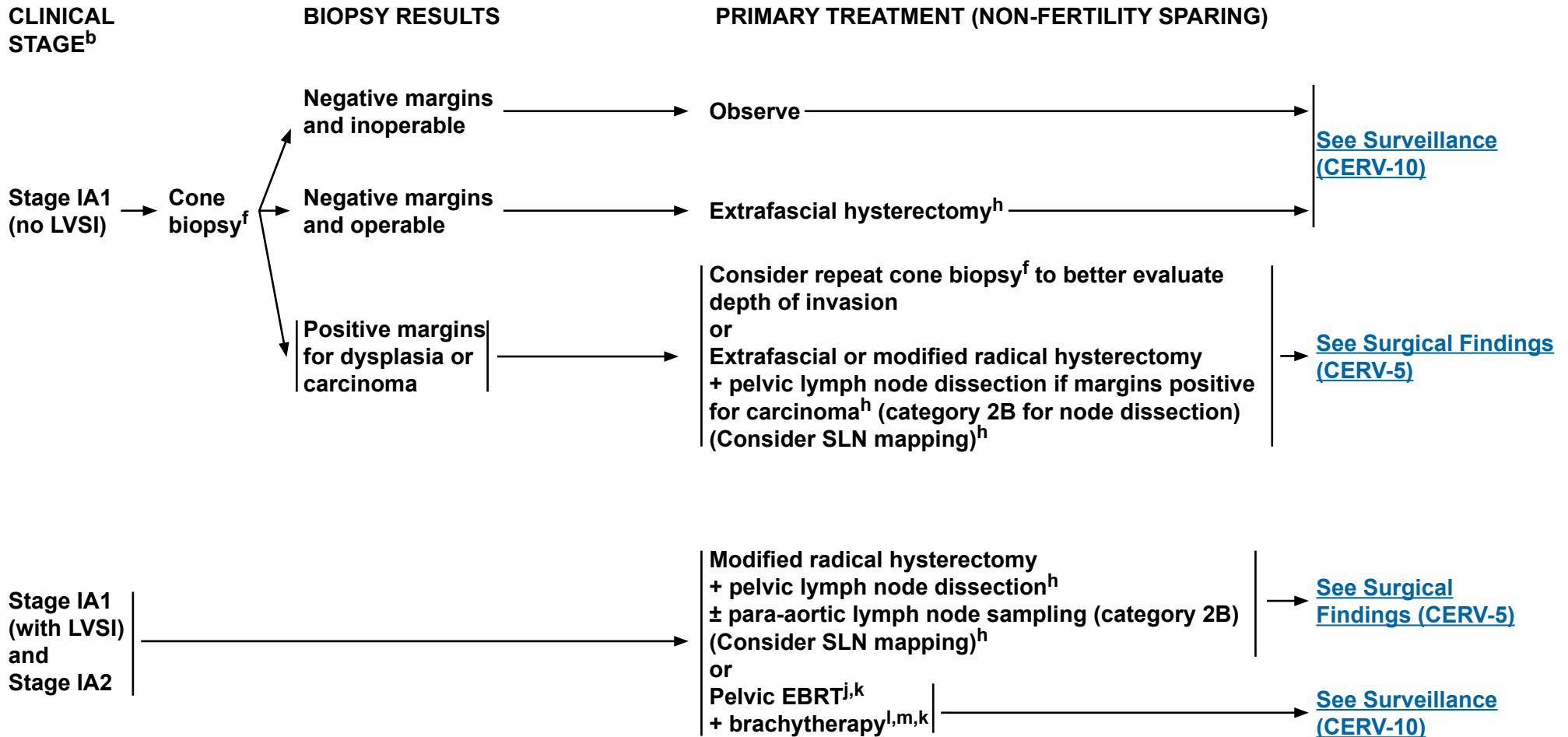
<sup>g</sup>Negative for invasive disease or histologic high-grade squamous intraepithelial lesion (HSIL) at margins.

<sup>h</sup>[See Principles of Evaluation and Surgical Staging \(CERV-B\).](#)

<sup>i</sup>For SLN mapping, the best detection rates and mapping results are in tumors <2 cm.

**Note: All recommendations are category 2A unless otherwise indicated.**  
**Clinical Trials: NCCN believes that the best management of any patient with cancer is in a clinical trial. Participation in clinical trials is especially encouraged.**





<sup>b</sup>See Principles of Imaging (CERV-A).

<sup>f</sup>Cold knife conization (CKC) is the preferred method of diagnostic excision, but loop electrosurgical excision procedure (LEEP) is acceptable, provided adequate margins and proper orientation are obtained. Endocervical curettage (ECC) should be added as clinically indicated.

<sup>h</sup>See Principles of Evaluation and Surgical Staging (CERV-B).

<sup>j</sup>Radiation can be an option for medically inoperable patients or those who refuse surgery.

<sup>k</sup>See Principles of Radiation Therapy for Cervical Cancer (CERV-C).

<sup>l</sup>These doses are recommended for most patients based on summation of conventional external-beam fractionation and low-dose-rate (40–70 cGy/h) brachytherapy equivalents. Modify treatment based on normal tissue tolerance, fractionation, and size of target volume. (See Discussion)

<sup>m</sup>The traditional dose would be 70–80 Gy to total point A dose.

**Note: All recommendations are category 2A unless otherwise indicated.**

**Clinical Trials: NCCN believes that the best management of any patient with cancer is in a clinical trial. Participation in clinical trials is especially encouraged.**

CLINICAL STAGE <sup>b</sup>	PRIMARY TREATMENT (NON-FERTILITY SPARING)	
<b>Stage IB1 and Stage IIA1</b>	<b>Radical hysterectomy + pelvic lymph node dissection<sup>h</sup></b> <b>(category 1)</b> <b>± para-aortic lymph node sampling (category 2B)</b> <b>(Consider SLN mapping)<sup>h,i</sup></b> <b>or</b> <b>Pelvic EBRT<sup>j,k</sup></b> <b>+ brachytherapy (total point A dose: 80–85 Gy)<sup>l,k</sup></b> <b>± concurrent cisplatin-containing chemotherapy<sup>n</sup></b>	<a href="#">See Surgical Findings (CERV-5)</a>
	<b>± concurrent cisplatin-containing chemotherapy<sup>n</sup></b>	<a href="#">See Surveillance (CERV-10)</a>
<b>Stage IB2 and Stage IIA2</b> <b>(also see <a href="#">CERV-6</a> for additional recommendations for non-primary surgery patients)</b>	<b>Definitive pelvic EBRT<sup>k</sup></b> <b>+ concurrent cisplatin-containing chemotherapy<sup>n</sup></b> <b>+ brachytherapy (total point A dose ≥85 Gy)<sup>l,k</sup></b> <b>(category 1 for primary chemoradiation)</b> <b>or</b>	<a href="#">See Surveillance (CERV-10)</a>
	<b>Radical hysterectomy</b> <b>+ pelvic lymph node dissection<sup>h</sup></b> <b>± para-aortic lymph node sampling (category 2B)</b> <b>or</b>	<a href="#">See Surgical Findings (CERV-5)</a>
	<b>Pelvic EBRT<sup>k</sup></b> <b>+ concurrent cisplatin-containing chemotherapy<sup>n</sup></b> <b>+ brachytherapy<sup>l,o,k</sup></b> <b>+ adjuvant hysterectomy<sup>p</sup></b> <b>(category 3)</b>	<a href="#">See Surveillance (CERV-10)</a>

<sup>b</sup>See [Principles of Imaging \(CERV-A\)](#).

<sup>h</sup>See [Principles of Evaluation and Surgical Staging \(CERV-B\)](#).

<sup>i</sup>For SLN mapping, the best detection rates and mapping results are in tumors <2 cm.

<sup>j</sup>Radiation can be an option for medically inoperable patients or those who refuse surgery.

<sup>k</sup>See [Principles of Radiation Therapy for Cervical Cancer \(CERV-C\)](#).

<sup>l</sup>These doses are recommended for most patients based on summation of conventional external-beam fractionation and low-dose-rate (40–70 cGy/h) brachytherapy equivalents. Modify treatment based on normal tissue tolerance, fractionation, and size of target volume. ([See Discussion](#))

<sup>n</sup>Concurrent cisplatin-based chemotherapy with EBRT utilizes cisplatin as a single agent or cisplatin plus 5-fluorouracil.

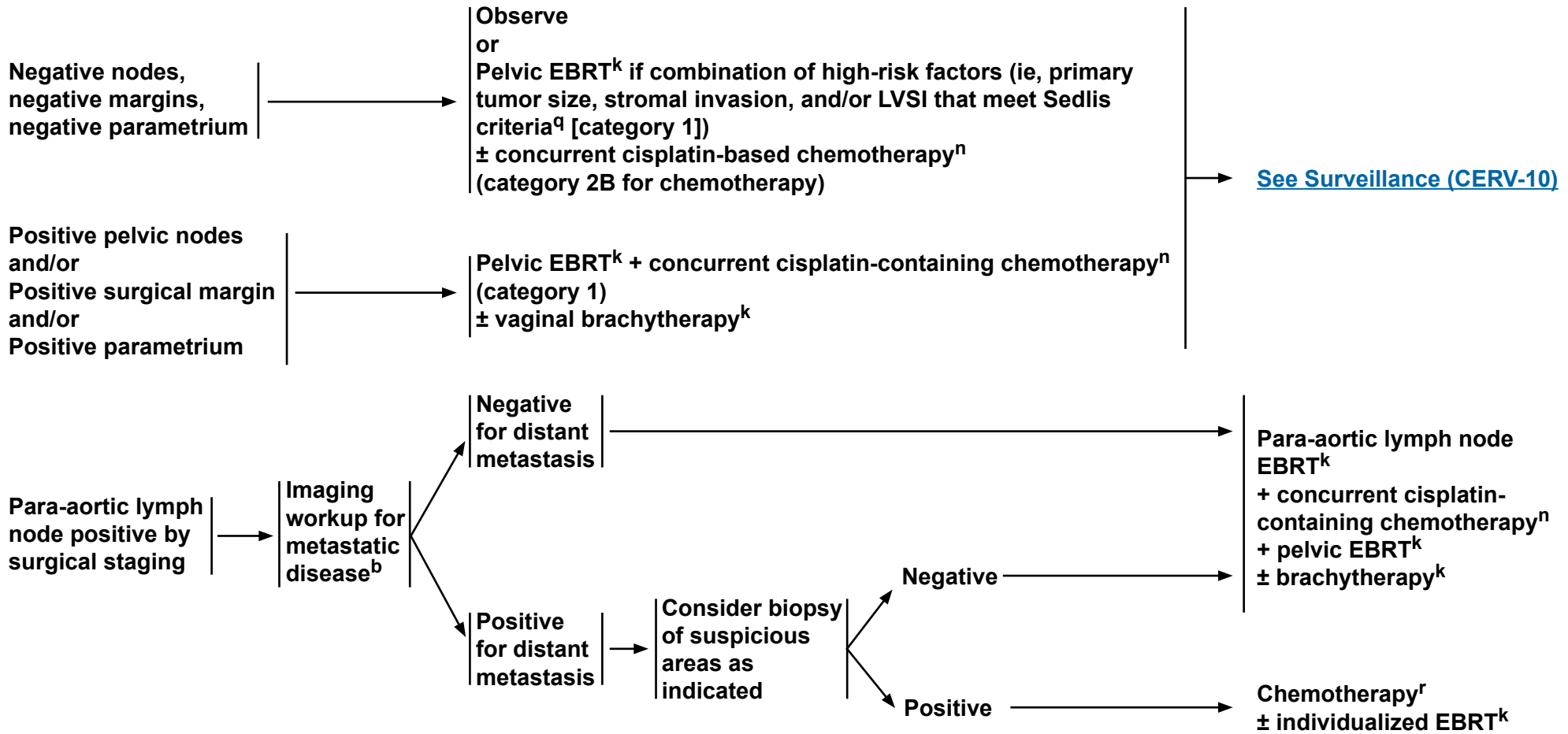
<sup>o</sup>The traditional dose would be 75–80 Gy to total point A dose.

<sup>p</sup>This approach can be considered in patients whose extent of disease or uterine anatomy precludes adequate coverage by brachytherapy.

**Note: All recommendations are category 2A unless otherwise indicated.**  
**Clinical Trials: NCCN believes that the best management of any patient with cancer is in a clinical trial. Participation in clinical trials is especially encouraged.**

**SURGICAL FINDINGS**

**ADJUVANT TREATMENT**



<sup>b</sup>See Principles of Imaging (CERV-A).

<sup>k</sup>See Principles of Radiation Therapy for Cervical Cancer (CERV-C).

<sup>n</sup>Concurrent cisplatin-based chemotherapy with EBRT utilizes cisplatin as a single agent or cisplatin plus 5-fluorouracil.

<sup>q</sup>Risk factors may not be limited to the Sedlis criteria. See Sedlis Criteria (CERV-D).

<sup>r</sup>See Chemotherapy Regimens for Recurrent or Metastatic Cervical Cancer (CERV-E).

**Note:** All recommendations are category 2A unless otherwise indicated.

**Clinical Trials:** NCCN believes that the best management of any patient with cancer is in a clinical trial. Participation in clinical trials is especially encouraged.

[See Surveillance \(CERV-10\)](#)

**CLINICAL STAGE**

**ADDITIONAL WORKUP**

**PRIMARY TREATMENT**

Stage IB2, Stage IIA2  
(See [CERV-4](#) for alternative  
recommendations for these patients)  
Stage IIB, IIIA, IIIB, IVA

Radiologic  
imaging only<sup>b</sup>

Negative  
adenopathy

Pelvic EBRT<sup>k</sup>  
+ concurrent cisplatin-containing chemotherapy<sup>n</sup>  
+ brachytherapy<sup>k</sup>  
(category 1)

Positive  
adenopathy

Consider needle  
biopsy

[See Imaging  
Results \(CERV-7\)](#)

or

Surgical staging  
(category 2B):  
Extraperitoneal  
or laparoscopic  
lymph node  
dissection

Negative

Pelvic EBRT<sup>k</sup>  
+ concurrent cisplatin-containing chemotherapy<sup>n</sup>  
+ brachytherapy<sup>k</sup>  
(category 1)

Positive

[See Node Status  
\(CERV-8\)](#)

<sup>b</sup>See [Principles of Imaging \(CERV-A\)](#).

<sup>k</sup>See [Principles of Radiation Therapy for Cervical Cancer \(CERV-C\)](#).

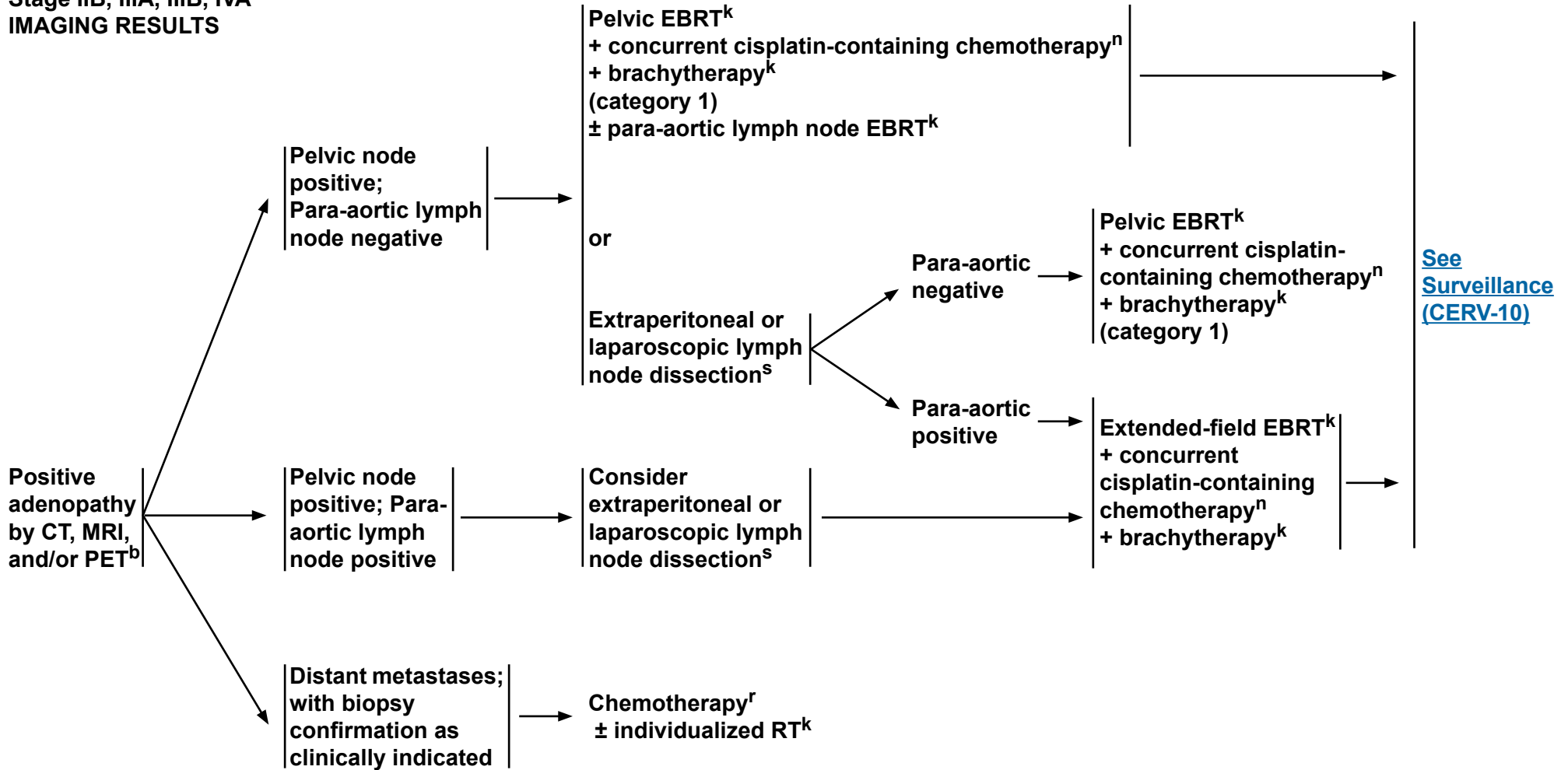
<sup>n</sup>Concurrent cisplatin-based chemotherapy with EBRT utilizes cisplatin as a single agent or cisplatin plus 5-fluorouracil.

**Note: All recommendations are category 2A unless otherwise indicated.**  
**Clinical Trials: NCCN believes that the best management of any patient with cancer is in a clinical trial. Participation in clinical trials is especially encouraged.**

[See Surveillance  
\(CERV-10\)](#)

**Stage IB2, IIA2**  
**Stage IIB, IIIA, IIIB, IVA**  
**IMAGING RESULTS**

**PRIMARY TREATMENT**



<sup>b</sup>See Principles of Imaging (CERV-A).

<sup>k</sup>See Principles of Radiation Therapy for Cervical Cancer (CERV-C).

<sup>n</sup>Concurrent cisplatin-based chemotherapy with EBRT utilizes cisplatin as a single agent or cisplatin plus 5-fluorouracil.

<sup>r</sup>See Chemotherapy Regimens for Recurrent or Metastatic Cervical Cancer (CERV-E).

<sup>s</sup>Consider postoperative imaging (abdominal/pelvic CT or MRI with contrast) to confirm the adequacy of node removal.

**Note:** All recommendations are category 2A unless otherwise indicated.  
**Clinical Trials:** NCCN believes that the best management of any patient with cancer is in a clinical trial. Participation in clinical trials is especially encouraged.

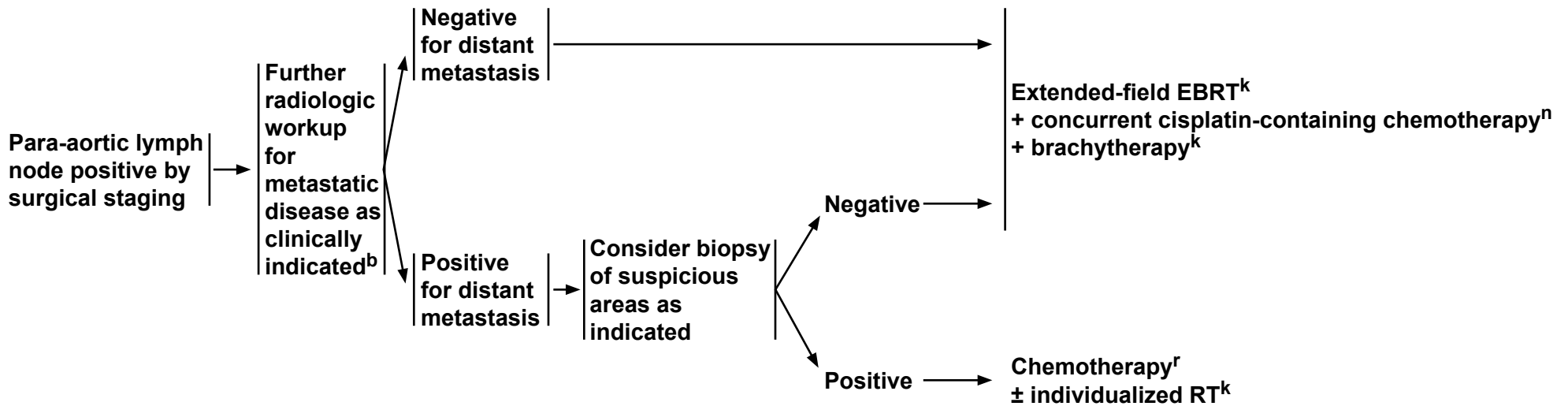
[See Surveillance \(CERV-10\)](#)

**Stage IB2, IIA2; Stage IIB, IIIA, IIIB, IVA**  
**NODE STATUS**

**PRIMARY TREATMENT**

Pelvic lymph node positive  
and para-aortic lymph  
node negative by surgical  
staging

Pelvic EBRT<sup>k</sup>  
+ concurrent cisplatin-containing chemotherapy<sup>n</sup>  
+ brachytherapy<sup>k</sup>  
(category 1)



<sup>b</sup>See Principles of Imaging (CERV-A).

<sup>k</sup>See Principles of Radiation Therapy for Cervical Cancer (CERV-C).

<sup>n</sup>Concurrent cisplatin-based chemotherapy with EBRT utilizes cisplatin as a single agent or cisplatin plus 5-fluorouracil.

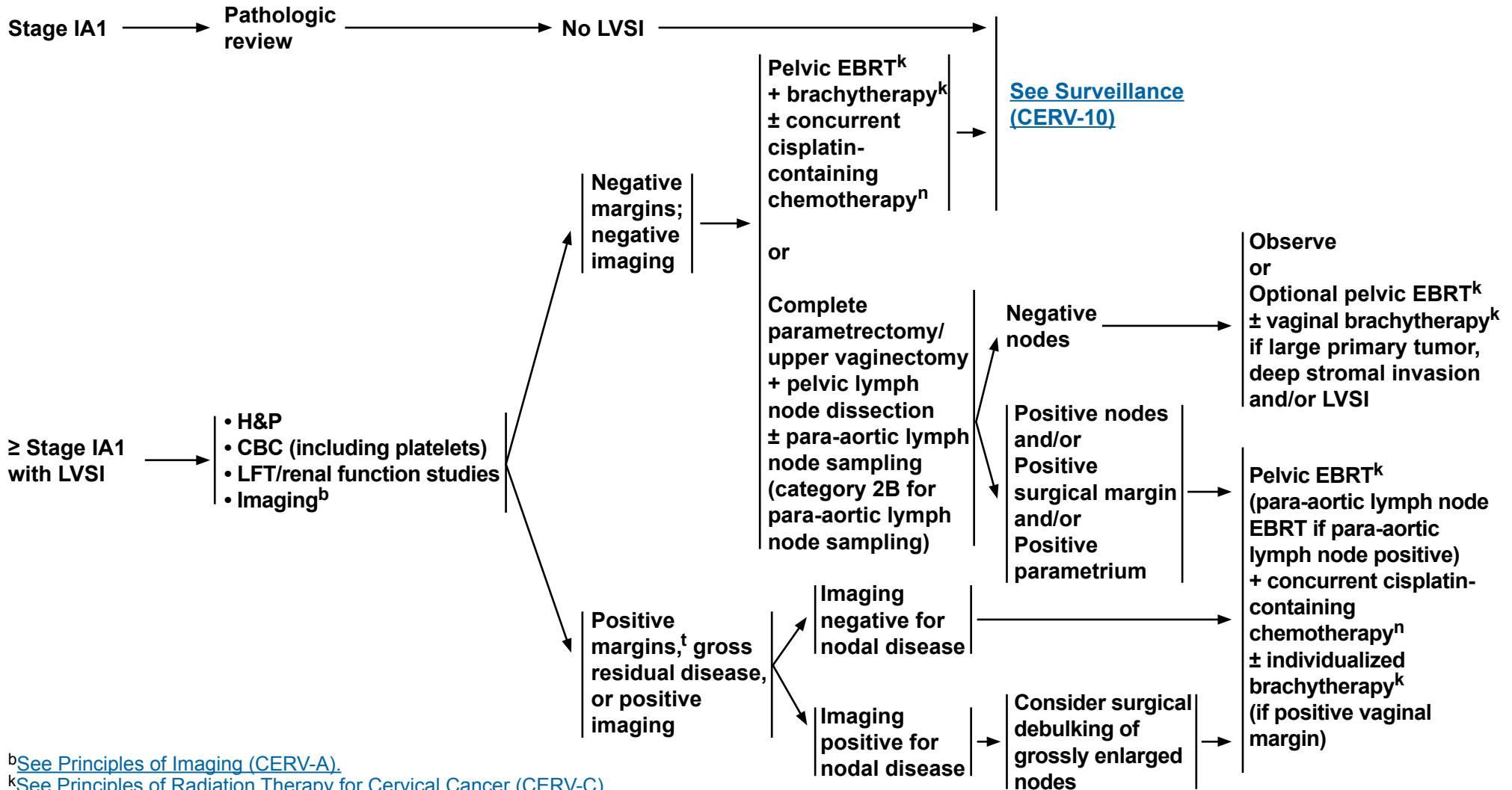
<sup>r</sup>See Chemotherapy Regimens for Recurrent or Metastatic Cervical Cancer (CERV-E).

**Note:** All recommendations are category 2A unless otherwise indicated.  
**Clinical Trials:** NCCN believes that the best management of any patient with cancer is in a clinical trial. Participation in clinical trials is especially encouraged.

[See Surveillance \(CERV-10\)](#)

**INCIDENTAL FINDING OF INVASIVE CANCER  
AFTER SIMPLE HYSTERECTOMY**

**TREATMENT**



<sup>b</sup>See Principles of Imaging (CERV-A).

<sup>k</sup>See Principles of Radiation Therapy for Cervical Cancer (CERV-C).

<sup>n</sup>Concurrent cisplatin-based chemotherapy with EBRT utilizes cisplatin as a single agent or cisplatin plus 5-fluorouracil.

<sup>†</sup>Invasive cancer at surgical margin.

**Note:** All recommendations are category 2A unless otherwise indicated.  
**Clinical Trials:** NCCN believes that the best management of any patient with cancer is in a clinical trial. Participation in clinical trials is especially encouraged.

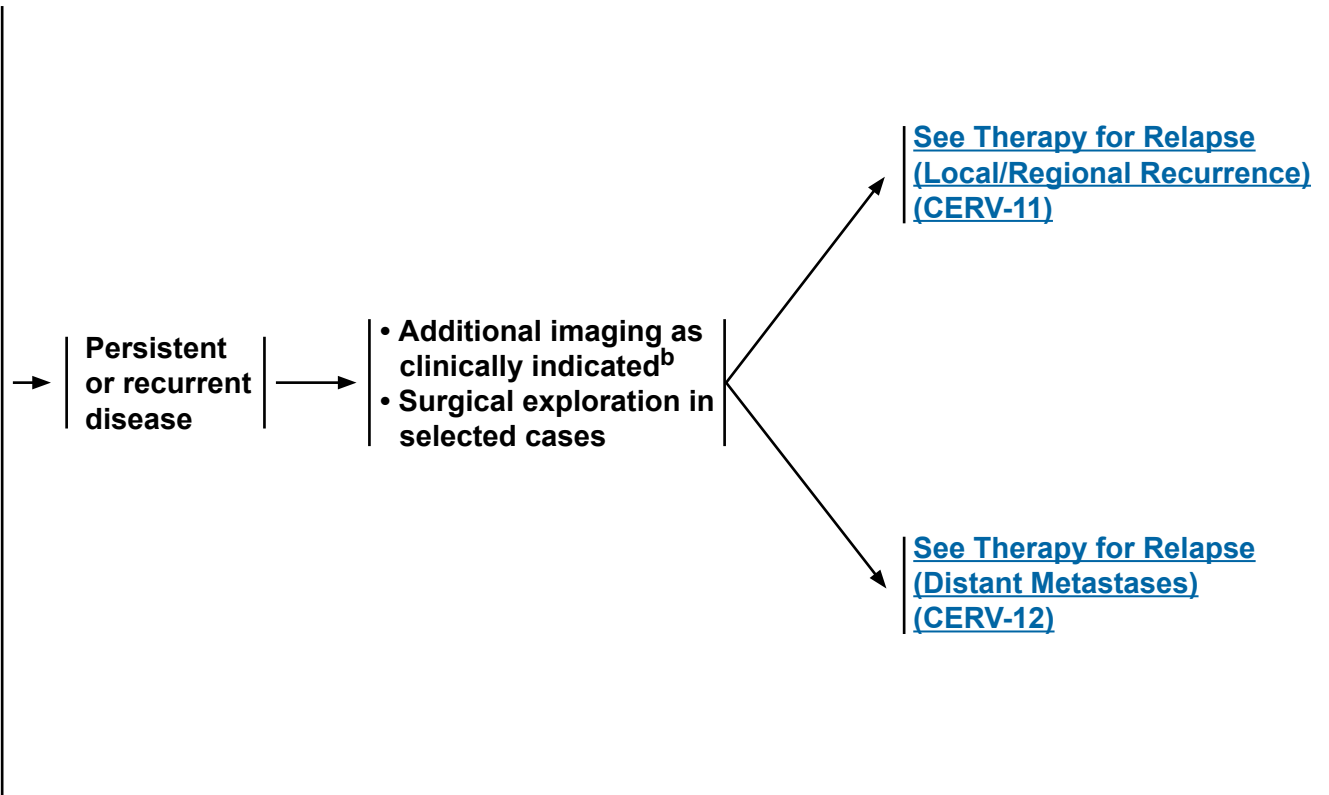
[See Surveillance \(CERV-10\)](#)



## SURVEILLANCE<sup>u</sup>

- Interval H&P every 3–6 mo for 2 y, every 6–12 mo for 3–5 y, then annually based on patient’s risk of disease recurrence
- Cervical/vaginal cytology annually<sup>v</sup> as indicated for the detection of lower genital tract neoplasia
- Imaging as indicated based on symptoms or examination findings suspicious for recurrence<sup>b,w</sup>
- Laboratory assessment (CBC, blood urea nitrogen [BUN], creatinine) as indicated based on symptoms or examination findings suspicious for recurrence
- Patient education regarding symptoms of potential recurrence, periodic self-examinations, lifestyle, obesity, exercise, sexual health (including vaginal dilator use and lubricants/moisturizers), smoking cessation, nutrition counseling, and potential long-term and late effects of treatment ([See NCCN Guidelines for Survivorship and NCCN Guidelines for Smoking Cessation](#))

## WORKUP



<sup>b</sup>See Principles of Imaging (CERV-A).

<sup>u</sup>Salani R, Backes FJ, Fung MF, et al. Posttreatment surveillance and diagnosis of recurrence in women with gynecologic malignancies: Society of Gynecologic Oncologists recommendations. Am J Obstet Gynecol 2011;204:466-478.

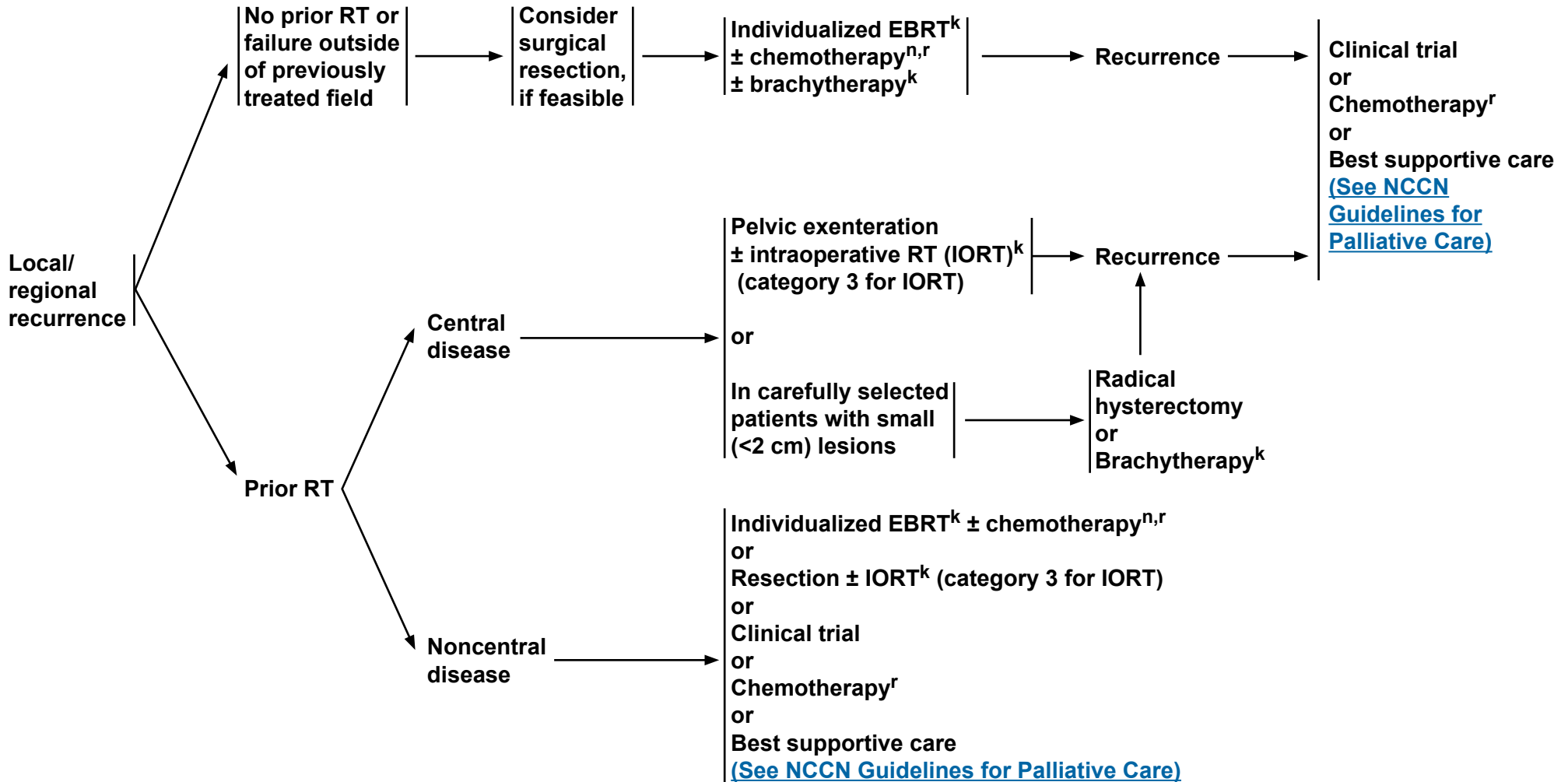
<sup>v</sup>Regular cytology can be considered for detection of lower genital tract dysplasia, although its value in detection of recurrent cervical cancer is limited. The likelihood of picking up asymptomatic recurrences by cytology alone is low.

<sup>w</sup>Recurrences should be proven by biopsy before proceeding to treatment planning.

**Note:** All recommendations are category 2A unless otherwise indicated.

**Clinical Trials:** NCCN believes that the best management of any patient with cancer is in a clinical trial. Participation in clinical trials is especially encouraged.

**THERAPY FOR RELAPSE**

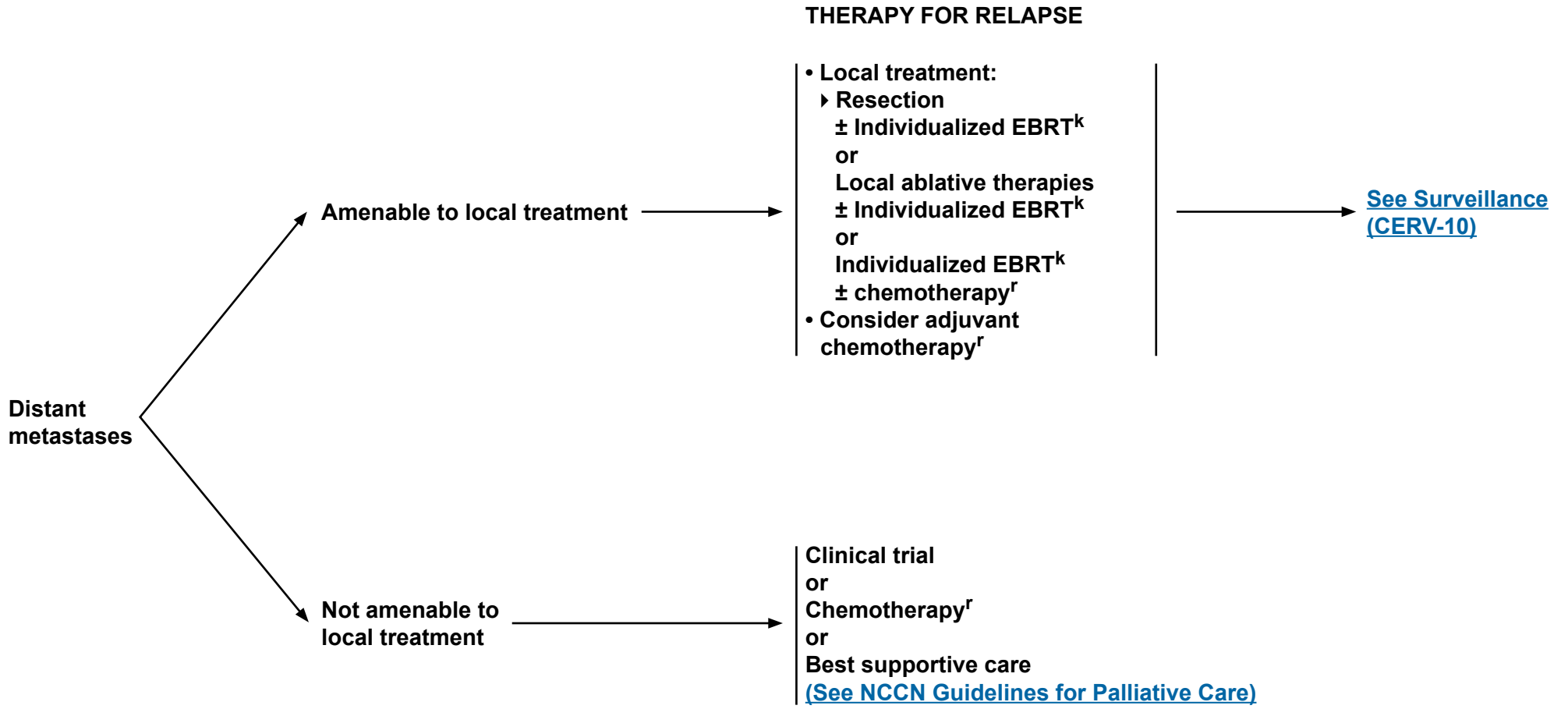


<sup>k</sup>[See Principles of Radiation Therapy for Cervical Cancer \(CERV-C\).](#)

<sup>n</sup>Concurrent cisplatin-based chemotherapy with EBRT utilizes cisplatin as a single agent or cisplatin plus 5-fluorouracil.

<sup>r</sup>[See Chemotherapy Regimens for Recurrent or Metastatic Cervical Cancer \(CERV-E\).](#)

**Note:** All recommendations are category 2A unless otherwise indicated.  
**Clinical Trials:** NCCN believes that the best management of any patient with cancer is in a clinical trial. Participation in clinical trials is especially encouraged.



<sup>k</sup>See Principles of Radiation Therapy for Cervical Cancer (CERV-C).

<sup>r</sup>See Chemotherapy Regimens for Recurrent or Metastatic Cervical Cancer (CERV-E).

**Note:** All recommendations are category 2A unless otherwise indicated.  
**Clinical Trials:** NCCN believes that the best management of any patient with cancer is in a clinical trial. Participation in clinical trials is especially encouraged.

**PRINCIPLES OF IMAGING\***<sup>1-8</sup>

**Initial Workup**

• **Stage I**

▶ **Non-Fertility Sparing**

- ◇ Consider chest imaging with plain radiography (chest x-ray). If an abnormality is seen then chest CT without contrast may be performed.
- ◇ Optional pelvic MRI with contrast to assess local disease extent (preferred for FIGO stage IB2).
- ◇ Consider whole body PET/CT or chest/abdomen/pelvic CT in FIGO stage IB2
- ◇ For patients who underwent total hysterectomy (TH) with incidental finding of cervical cancer consider whole body PET/CT or chest/abdomen/pelvic CT to evaluate for metastatic disease and pelvic MRI to assess pelvic residual disease.

▶ **Fertility Sparing**

- ◇ Consider chest imaging with plain radiography (chest x-ray). If an abnormality is seen then chest CT without contrast may be performed.
- ◇ Pelvic MRI (preferred) to assess local disease extent and proximity of tumor to internal cervical os; pelvic transvaginal ultrasound if MRI contraindicated.
- ◇ Other imaging should be based on symptomatology and clinical concern for metastatic disease.\*\*

• **Stage II-IV**

- ▶ Whole body PET/CT (preferred) or chest/abdomen/pelvic CT to evaluate for metastatic disease.
- ▶ Consider pelvic MRI with contrast to assess local disease extent.
- ▶ Other initial imaging should be based on symptomatology and clinical concern for metastatic disease.\*\*\*
- ▶ For patients who underwent TH with incidental finding of cervical cancer consider whole body PET/CT or chest/abdomen/pelvic CT to evaluate for metastatic disease and pelvic MRI with contrast to assess pelvic residual disease.

\*MRI and CT are performed with contrast throughout the guidelines unless contraindicated. Contrast is not required for screening chest CT.

\*\*These factors may include abnormal physical exam findings or pelvic, abdominal, or pulmonary symptoms.

\*\*\*These factors may include abnormal physical exam findings, bulky pelvic tumor (>4 cm), delay in presentation or treatment, and pelvic abdominal or pulmonary symptoms.

**Note:** All recommendations are category 2A unless otherwise indicated.

**Clinical Trials:** NCCN believes that the best management of any patient with cancer is in a clinical trial. Participation in clinical trials is especially encouraged.

[Continued](#)

**CERV-A**  
**1 OF 3**

**PRINCIPLES OF IMAGING<sup>\*,1-8</sup>**

**Follow-up/Surveillance**

**• Stage I**

**▶ Non-Fertility Sparing**

- ◊ Imaging should be based on symptomatology and clinical concern for recurrent/metastatic disease.<sup>†</sup>
- ◊ For patients with FIGO stage IB2 or patients who required postoperative adjuvant radiation or chemoradiation due to high-risk factors,<sup>††</sup> a whole body PET/CT may be performed at 3–6 months after completion of treatment.

**▶ Fertility-Sparing**

- ◊ Consider pelvic MRI with contrast 6 months after surgery and then yearly for 2–3 years.
- ◊ Consider whole body PET/CT if metastasis is suspected.
- ◊ Other imaging should be based on symptomatology and clinical concern for recurrent/metastatic disease.<sup>†</sup>

**• Stage II-IV**

- ▶ Whole body PET/CT (preferred) or chest/abdomen/pelvic CT with contrast within 3–6 months of completion of therapy.
- ▶ Optional pelvic MRI with contrast at 3–6 months post completion of therapy.
- ▶ Other imaging should be based on symptomatology and clinical concern for recurrent/metastatic disease.<sup>†††</sup>

\*MRI and CT are performed with contrast throughout the guidelines unless contraindicated. Contrast is not required for screening chest CT.

†These factors may include abnormal physical exam findings or new pelvic, abdominal, or pulmonary symptoms.

††Risk factors may include positive nodes, positive parametria, positive margins, or local cervical factors ([See Sedlis Criteria CERV-D](#)).

†††These factors may include abnormal physical exam findings such as palpable mass or adenopathy, or new pelvic, abdominal, or pulmonary symptoms.

**Note: All recommendations are category 2A unless otherwise indicated.**

**Clinical Trials: NCCN believes that the best management of any patient with cancer is in a clinical trial. Participation in clinical trials is especially encouraged.**

[Continued](#)

**CERV-A**  
**2 OF 3**

**PRINCIPLES OF IMAGING**  
**(References)**

- <sup>1</sup>Salani R, Backes FJ, Fung MF, et al. Posttreatment surveillance and diagnosis of recurrence in women with gynecologic malignancies: Society of Gynecologic Oncologists recommendations. *Am J Obstet Gynecol* 2011;204:466-478.
- <sup>2</sup>Atri M, Zhang Z, Dehdashti F, et al. Utility of PET-CT to Evaluate Retroperitoneal Lymph Node Metastasis in Advanced Cervical Cancer: Results of ACRIN6671/GOG0233 Trial. *Gynecol Oncol*. 2016;142:413-419.
- <sup>3</sup>Rajendran JG, Greer BE. Expanding role of positron emission tomography in cancer of the uterine cervix. *J Natl Compr Canc Netw* 2006;4:463-469.
- <sup>4</sup>Lakhman Y, Akin O, Park KJ, et al. Stage IB1 cervical cancer: role of preoperative MR imaging in selection of patients for fertility-sparing radical trachelectomy. *Radiology* 2013;269:149-158.
- <sup>5</sup>Elit L, Reade CJ. Recommendations for Follow-up Care for Gynecologic Cancer Survivors. *Obstet Gynecol* 2015;126:1207-1214.
- <sup>6</sup>Sala E, Rockall AG, Freeman SJ, et al. The added role of MR imaging in treatment stratification of patients with gynecologic malignancies: what the radiologist needs to know. *Radiology* 2013;266:717-740.
- <sup>7</sup>Balleyguier C, Sala E, Da Cunha T, et al. Staging of uterine cervical cancer with MRI: Guidelines of the European Society of Urogenital Radiology. *Eur Radiol* 2011;21:1102-1110.
- <sup>8</sup>Sala E, Micco M, Burger IA, et al. Complementary prognostic value of pelvic MRI and whole-body FDG PET/CT in the pretreatment assessment of patients with cervical cancer. *Int J Gynecol Oncol* 2015;25:1461-1467.

**Note: All recommendations are category 2A unless otherwise indicated.**

**Clinical Trials: NCCN believes that the best management of any patient with cancer is in a clinical trial. Participation in clinical trials is especially encouraged.**

**PRINCIPLES OF EVALUATION AND SURGICAL STAGING**

**Types of Resection and Appropriateness for Treatment of Cervical Cancer**

- Treatment of cervical cancer is stratified by stage as delineated in the Guidelines.
- Microinvasive disease, defined as FIGO stage IA-1 with no lymphovascular invasion (LVSI), has less than a 1% chance of lymphatic metastasis and may be managed conservatively with cone biopsy for preservation of fertility (with negative margins) or with simple hysterectomy when preservation of fertility is not desired or relevant. The intent of a cone biopsy is to remove the ectocervix and endocervical canal *en bloc* using a scalpel. This provides the pathologist with an intact, non-fragmented specimen without electrosurgical artifact, which facilitates margin status evaluation. If a loop electrosurgical excision procedure (LEEP) is chosen for treatment, the specimen should not be fragmented, and care must be undertaken to minimize electrosurgical artifact at the margins. The shape and depth of the cone biopsy may be tailored to the size, type, and location of the neoplastic lesion. For example, if there is concern for invasive adenocarcinoma versus adenocarcinoma *in situ* in the cervical canal, the cone biopsy would be designed as a narrow, long cone extending to the internal os in order not to miss possible invasion in the endocervical canal. Cone biopsy is indicated for triage and treatment of small cancers where there is no likelihood of cutting across gross neoplasm. In cases of stage IA1 with LVSI, a conization (with negative margins) with laparoscopic pelvic SLN mapping/lymphadenectomy is a reasonable strategy.
- Radical hysterectomy with bilateral pelvic lymph node dissection (with or without SLN mapping) is the preferred treatment for FIGO stage IA-2, IB, and IIA lesions when fertility preservation is not desired. Radical hysterectomy results in resection of much wider margins compared with a simple hysterectomy, including removal of parts of the cardinal and uterosacral ligaments and the upper 1–2 cm of the vagina; in addition, pelvic and sometimes para-aortic nodes are removed. Radical hysterectomy procedures may be performed either via laparotomy or laparoscopy, and the laparoscopy approach may be either with conventional or robotic techniques. The Querleu & Morrow classification system<sup>1</sup> is a modern surgical classification that describes degree of resection and nerve preservation in 3-dimensional planes of resection.<sup>2</sup> Procedural details for the most commonly used types of hysterectomy are described in Table 1 ([see CERV-B 5 of 7](#)).
- The radical vaginal trachelectomy with laparoscopic lymphadenectomy procedure (with or without SLN mapping) offers a fertility-sparing option for carefully selected individuals with stage IA-2 or stage IB-1 lesions of 2 cm diameter or less. The cervix, upper vagina, and supporting ligaments are removed as with a type B radical hysterectomy, but the uterine corpus is preserved. In the more than 300 subsequent pregnancies currently reported, there is a 10% likelihood of second trimester loss, but 72% of patients carry their gestation to 37 weeks or more.<sup>3</sup> The abdominal radical trachelectomy has emerged as a reasonable fertility-sparing strategy. It provides larger resection of parametria than the vaginal approach,<sup>4</sup> is suitable for select stage IB1 cases, and has been utilized in lesions up to 4 cm in diameter. The operation mimics a type C radical hysterectomy.<sup>\*,1,2,5-8</sup>

\*For a description of a type C radical hysterectomy, [see Table 1 \(CERV-B 5 of 7\)](#).

**Note:** All recommendations are category 2A unless otherwise indicated.

**Clinical Trials:** NCCN believes that the best management of any patient with cancer is in a clinical trial. Participation in clinical trials is especially encouraged.

[Continued](#)

**CERV-B**  
**1 OF 7**



**PRINCIPLES OF EVALUATION AND SURGICAL STAGING****Types of Resection and Appropriateness for Treatment of Cervical Cancer--continued**

- **Advanced-stage disease, including FIGO stage IIB and above, is not usually treated with hysterectomy, as delineated in the Guidelines. The majority of advanced-stage disease in the United States is treated with definitive chemoradiation. In some countries, select cases of stage IIB may be treated with upfront radical hysterectomy or neoadjuvant chemotherapy followed by radical hysterectomy.**
- **Recurrent or persistent disease in the central pelvis following radiation therapy may potentially be cured with the pelvic exenteration procedure. Preoperative assessment for exenteration is designed to identify or rule out distant metastasis. If the recurrence is confined to the pelvis, then surgical exploration is carried out. If intraoperative margin and node assessment are negative, then resection of pelvic viscera is completed. Depending on the location of the tumor, resection may include anterior exenteration, posterior exenteration, or total pelvic exenteration. In cases where the location of tumor allows adequate margins, the pelvic floor and anal sphincter may be preserved as a supra-levator exenteration. Table 2 summarizes the tissues typically removed with differing types of pelvic exenteration ([See CERV-B 6 of 7](#)). These are highly complex procedures and should be performed in centers with a high level of expertise for exenteration procedures. Primary pelvic exenteration (without prior pelvic radiation) is restricted to the rare case where pelvic radiation is contraindicated or to women who received prior pelvic radiation for another indication and then developed a metachronous, locally advanced cervical carcinoma and further radiation therapy is not feasible.**

**Note: All recommendations are category 2A unless otherwise indicated.**

**Clinical Trials: NCCN believes that the best management of any patient with cancer is in a clinical trial. Participation in clinical trials is especially encouraged.**

[Continued](#)

**CERV-B**  
**2 OF 7**

**PRINCIPLES OF EVALUATION AND SURGICAL STAGING**

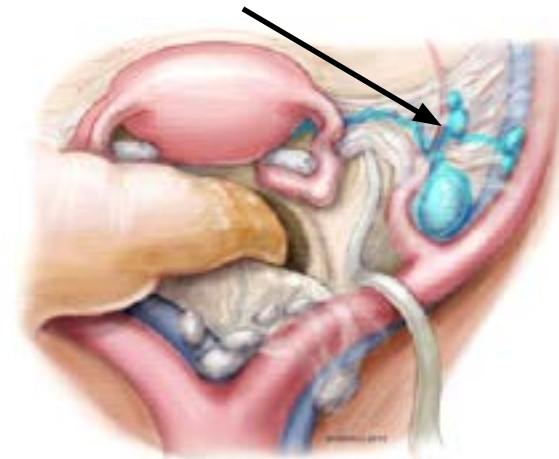
**Sentinel Lymph Node Mapping for Cervical Cancer:**

- SLN mapping as part of the surgical management of select stage I cervical cancer is considered in gynecologic oncology practices worldwide. While this technique has been used in tumors up to 4 cm in size, the best detection rates and mapping results are in tumors less than 2 cm.<sup>9-12</sup> This simple technique utilizes a direct cervical injection with dye or radiocolloid Technetium-99 (99Tc) into the cervix, usually at 2 or 4 points as shown in Figure 1 (below). The SLNs are identified at the time of surgery with direct visualization of colored dye, a fluorescent camera if indocyanine green (ICG) was used, or a gamma probe if 99Tc was used. SLNs following a cervical injection are commonly located medial to the external iliac vessels, ventral to the hypogastric vessels, or in the superior part of the obturator space (Figure 2). SLNs usually undergo ultrastaging by pathologists, which allows for higher detection of micrometastasis that may alter postoperative management.<sup>2,13</sup>

**Figure 1: Options of SLN Cervical Injection Sites†**



**Figure 2: SLNs (blue, arrow) After Cervical Injection Are Commonly Located Medial to the External Iliac, Ventral to the Hypogastric, or in the Superior Part of the Obturator Space†**



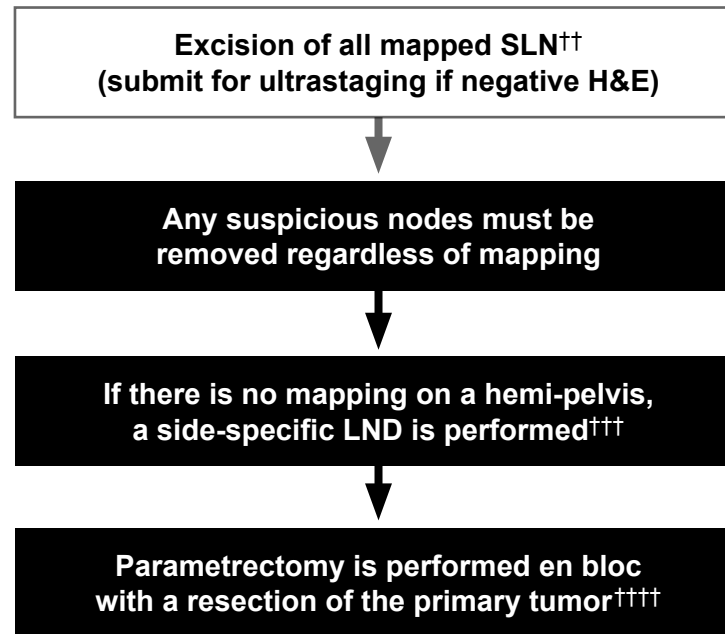
†Figures 1 and 2 are reproduced with permission from Memorial Sloan Kettering Cancer Center. © 2013 Memorial Sloan Kettering Cancer Center.

**Note: All recommendations are category 2A unless otherwise indicated.**  
**Clinical Trials: NCCN believes that the best management of any patient with cancer is in a clinical trial. Participation in clinical trials is especially encouraged.**

**PRINCIPLES OF EVALUATION AND SURGICAL STAGING WHEN SLN MAPPING IS USED**

The key to a successful SLN mapping is adherence to the SLN algorithm, which requires the performance of a side-specific nodal dissection in cases of failed mapping and removal of any suspicious or grossly enlarged nodes regardless of mapping (Figure 3).

**Figure 3: Surgical/SLN Mapping Algorithm for Early-Stage Cervical Cancer†**



H&E: Hematoxylin and eosin staining  
LND: Lymphadenectomy  
SLN: Sentinel lymph node

†Reproduced with permission from Cormier B, Diaz JP, Shih K, et al. Establishing a sentinel lymph node mapping algorithm for the treatment of early cervical cancer. *Gynecol Oncol.* 2011 Aug;122:275-280.

††Intracervical injection with dye, 99m technetium, or both.

†††Including interiliac/subaortic nodes.

††††Exceptions made for select cases ([see CERV-A 1 of 7](#)).

**Note: All recommendations are category 2A unless otherwise indicated.**  
**Clinical Trials: NCCN believes that the best management of any patient with cancer is in a clinical trial. Participation in clinical trials is especially encouraged.**

[Continued](#)

**PRINCIPLES OF EVALUATION AND SURGICAL STAGING**

**TABLE 1: Resection of Cervical Cancer as Primary Therapy\***

Comparison of Hysterectomy Types				Comparison of Trachelectomy Types	
	Simple/Extrafascial Hysterectomy (Type A)**	Modified Radical Hysterectomy (Type B)**	Radical Hysterectomy (Type C)**	Simple Trachelectomy	Radical Trachelectomy***
Indication	Stage IA-1	Stage IA-1 with LVSI and IA-2	Local disease without obvious metastasis, including: Stage IB-1 and 2 Selected Stage IIA	HSIL and stage IA-1	Stage IA-2 and Stage IB-1 if ≤2 cm diameter and squamous histology
Intent	Curative for microinvasion	Curative for small lesions	Curative for larger lesions	Curative for microinvasion Fertility preserved	Curative for select stage IB-1 and IA-2 Fertility preserved
Uterus	Removed	Removed	Removed	Spared	Spared
Ovaries	Optional removal	Optional removal	Optional removal	Spared	Spared
Cervix	Removed	Removed	Removed	Removed	Removed
Vaginal margin	None	1–2 cm margin	Upper 1/4 to 1/3 of vagina	None	Upper 1/4 to 1/3 of vagina
Ureters	Not mobilized	Tunneled through broad ligament	Tunneled through broad ligament	Not mobilized	Tunneled through broad ligament
Cardinal ligaments	Resected at uterine and cervical border	Divided where ureter transits the broad ligament	Divided at pelvic sidewall	Resected at cervical border	Divided at pelvic sidewall
Uterosacral ligaments	Divided at cervical border	Partially resected	Divided near sacral origin	Divided at cervical border	Divided near sacral origin
Bladder	Mobilized to base of cervix	Mobilized to upper vagina	Mobilized to middle vagina	Mobilized to peritoneal reflection	Mobilized to peritoneal reflection
Rectum	Not mobilized	Mobilized below cervix	Mobilized below middle vagina	Mobilized to peritoneal reflection	Mobilized to above peritoneal reflection
Surgical approach	Laparotomy or laparoscopy	Laparotomy or laparoscopy or robotic laparoscopy	Laparotomy or laparoscopy or robotic laparoscopy	Vaginal	Vaginal or laparotomy or laparoscopy, or robotic laparoscopy

\*Data from Chi DS, Abu-Rustum NR, Plante M, Roy M. Cancer of the cervix. In: TeLinde's Operative Gynecology, 10th ed. Rock JA, Jones HW, eds. Philadelphia: Lippincott Williams and Wilkins;2008:1227.

\*\*The Querleu and Morrow surgical classification system describes the degree of resection and nerve preservation for radical hysterectomy in three-dimensional planes and updates the previously used Piver-Rutledge classifications.

\*\*\*Fertility-sparing radical trachelectomy is most validated for lesions ≤2 cm in diameter. Small cell neuroendocrine histology and adenoma malignum are not considered suitable tumors for this procedure.

**Note: All recommendations are category 2A unless otherwise indicated.**

**Clinical Trials: NCCN believes that the best management of any patient with cancer is in a clinical trial. Participation in clinical trials is especially encouraged.**

[Continued](#)

**CERV-B**  
**5 OF 7**

### PRINCIPLES OF EVALUATION AND SURGICAL STAGING

**TABLE 2: Resection of Recurrent Cervical Cancer with No Distant Metastasis\***

Comparison of Infra-levator Exenteration Types				Comparison of Supra-levator Exenteration Types	
	Anterior	Posterior	Total	Posterior	Total
Indication	Central pelvic recurrence Primary therapy for FIGO stage IVA				
Intent	Curative				
Uterus, tubes, ovaries	Removed if still present	Removed if still present	Removed if still present	Removed if still present	Removed if still present
Vagina	Removed	Removed	Removed	Removed	Removed
Bladder and urethra	Removed	Preserved	Removed	Preserved	Removed
Rectum	Preserved	Removed	Removed	Removed	Removed
Anal sphincter	Preserved	Removed	Removed	Preserved, anastomosis possible	Preserved, anastomosis possible
Reconstruction options Urinary system	Ileal conduit or Continent conduit	N/A	Ileal conduit or Continent conduit	N/A	Ileal conduit or Continent conduit
Reconstruction options GI system	N/A	End colostomy	End colostomy	End colostomy or anastomosis	End colostomy or anastomosis
Reconstruction options Vagina	Split-thickness skin graft with omental J-flap, or Myocutaneous flap (rectus, gracilis, etc.), or None				

\*Data from Chi DS, Abu-Rustum NR, Plante M, Roy M. Cancer of the cervix. In: TeLinde's Operative Gynecology, 10th ed. Rock JA, Jones HW, eds. Philadelphia: Lippincott Williams and Wilkins;2008:1227.

**Note: All recommendations are category 2A unless otherwise indicated.**  
**Clinical Trials: NCCN believes that the best management of any patient with cancer is in a clinical trial. Participation in clinical trials is especially encouraged.**

[Continued](#)

**PRINCIPLES OF EVALUATION AND SURGICAL STAGING**  
**(References)**

- <sup>1</sup>Querleu D, Morrow CP. Classification of radical hysterectomy. *Lancet Oncol* 2008;9:297.
- <sup>2</sup>Cibula D, Abu-Rustum NR, Benedetti-Panici P, et al. New classification system of radical hysterectomy: emphasis on a three-dimensional anatomic template for parametrial resection. *Gynecol Oncol* 2011;122:264-268.
- <sup>3</sup>Plante M, Gregoire J, Renaud MC, Roy M. The vaginal radical trachelectomy: an update of a series of 125 cases and 106 pregnancies. *Gynecol Oncol* 2011;121:290-297.
- <sup>4</sup>Einstein MH, Park KJ, Sonoda Y, et al. Radical vaginal versus abdominal trachelectomy for stage IB1 cervical cancer: a comparison of surgical and pathologic outcomes. *Gynecol Oncol* 2009;112:73-77.
- <sup>5</sup>Piver MS, Rutledge F, Smith JP. Five classes of extended hysterectomy for women with cervical cancer. *Obstet Gynecol* 1974;44:265-272.
- <sup>6</sup>Wethington SL, Sonoda Y, Park KJ, et al. Expanding the indications for radical trachelectomy: a report on 29 patients with stage IB1 tumors measuring 2 to 4 centimeters. *Int J Gynecol Cancer* 2013;23:1092-1098.
- <sup>7</sup>Wethington SL, Cibula D, Duska LR, et al. An international series on abdominal radical trachelectomy: 101 patients and 28 pregnancies. *Int J Gynecol Cancer* 2012;22:1251-1257.
- <sup>8</sup>Lintner B, Saso S, Tarnai L, et al. Use of abdominal radical trachelectomy to treat cervical cancer greater than 2 cm in diameter. *Int J Gynecol Cancer* 2013;23:1065-1070.
- <sup>9</sup>Bats AS, Mathevet P, Buenerd A, et al. The sentinel node technique detects unexpected drainage pathways and allows nodal ultrastaging in early cervical cancer: insights from the multicenter prospective SENTICOL study. *Ann Surg Oncol* 2013;20:413-422.
- <sup>10</sup>Eiriksson LR, Covens A. Sentinel lymph node mapping in cervical cancer: the future? *BJOG*. 2012 Jan;119:129-133.
- <sup>11</sup>Cormier B, Diaz JP, Shih K, et al. Establishing a sentinel lymph node mapping algorithm for the treatment of early cervical cancer. *Gynecol Oncol* 2011;122:275-280.
- <sup>12</sup>Altgassen C, Hertel H, Brandstädt A, et al. Multicenter validation study of the sentinel lymph node concept in cervical cancer: AGO Study Group. *Clin Oncol* 2008;26:2943-2951.
- <sup>13</sup>Cibula D, Abu-Rustum NR, Dusek L, et al. Prognostic significance of low volume sentinel lymph node disease in early-stage cervical cancer. *Gynecol Oncol* 2012;124:496-501.

**Note: All recommendations are category 2A unless otherwise indicated.**

**Clinical Trials: NCCN believes that the best management of any patient with cancer is in a clinical trial. Participation in clinical trials is especially encouraged.**

**PRINCIPLES OF RADIATION THERAPY**

**External Beam Radiation Therapy (EBRT)**

- The use of CT-based treatment planning and conformal blocking is considered the standard of care for EBRT. MRI is the best imaging modality for determining soft tissue and parametrial involvement in patients with advanced tumors. In patients who are not surgically staged, PET imaging is useful to help define the nodal volume of coverage.
- The volume of EBRT should cover the gross disease (if present), parametria, uterosacral ligaments, sufficient vaginal margin from the gross disease (at least 3 cm), presacral nodes, and other nodal volumes at risk. For patients with negative nodes on surgical or radiologic imaging, the radiation volume should include the entirety of the external iliac, internal iliac, and obturator nodal basins. For patients deemed at higher risk of lymph node involvement (eg, bulkier tumors; suspected or confirmed nodes confined to the low true pelvis), the radiation volume should be increased to cover the common iliacs as well. In patients with documented common iliac and/or para-aortic nodal involvement, extended-field pelvic and para-aortic radiotherapy is recommended, up to the level of the renal vessels (or even more cephalad as directed by involved nodal distribution).
- Coverage of microscopic nodal disease requires an EBRT dose of approximately 45 Gy (in conventional fractionation of 1.8–2.0 Gy daily), and highly conformal boosts of an additional 10–15 Gy may be considered for limited volumes of gross unresected adenopathy. For the majority of patients who receive EBRT for cervical cancer, concurrent cisplatin-based chemotherapy (either cisplatin alone, or cisplatin + 5-fluorouracil) is given during the time of EBRT.
- Intensity-modulated radiation therapy (IMRT) and similar highly conformal methods of dose delivery may be helpful in minimizing the dose to the bowel and other critical structures in the IMRT post-hysterectomy setting<sup>1</sup> and in treating the para-aortic nodes when necessary. These techniques can also be useful when high doses are required to treat gross disease in regional lymph nodes. However, conformal external beam therapies (such as IMRT) should not be used as routine alternatives to brachytherapy for treatment of central disease in patients with an intact cervix. Very careful attention to detail and reproducibility (including consideration of target and normal tissue definitions, patient and internal organ motion, soft tissue deformation, and rigorous dosimetric and physics quality assurance) is required for proper delivery of IMRT and related highly conformal technologies. Routine image guidance, such as cone-beam CT (CBCT), may be helpful in defining daily internal soft tissue positioning.
- Concepts regarding the gross target volume (GTV), clinical target volume (CTV), planning target volume (PTV), organs at risk (OARs), and dose-volume histogram (DVH) have been defined for use in conformal radiotherapy, especially for IMRT.
- Stereotactic body radiotherapy (SBRT) is an approach that allows delivery of very high doses of focused external beam radiation in 1–5 fractions and may be applied to isolated metastatic sites.<sup>2,3</sup>

[Continued](#)

**Note:** All recommendations are category 2A unless otherwise indicated.

**Clinical Trials:** NCCN believes that the best management of any patient with cancer is in a clinical trial. Participation in clinical trials is especially encouraged.



**PRINCIPLES OF RADIATION THERAPY****Brachytherapy**

- **Brachytherapy is a critical component of definitive therapy for all patients with primary cervical cancer who are not candidates for surgery. This is usually performed using an intracavitary approach, with an intrauterine tandem and vaginal colpostats. Depending on the patient and tumor anatomy, the vaginal component of brachytherapy in patients with an intact cervix may be delivered using ovoids, ring, or cylinder brachytherapy (combined with the intrauterine tandem). MRI imaging immediately preceding brachytherapy may be helpful in delineating residual tumor geometry. When combined with EBRT, brachytherapy is often initiated towards the latter part of treatment, when sufficient primary tumor regression has been noted to permit satisfactory brachytherapy apparatus geometry. In highly selected very early disease (ie, stage IA2), brachytherapy alone (without EBRT) may be an option.**
- **In rare cases, patients whose anatomy or tumor geometry renders intracavitary brachytherapy infeasible may be best treated using an interstitial approach; however, such interstitial brachytherapy should only be performed by individuals and at institutions with appropriate experience and expertise.**
- **In selected post-hysterectomy patients (especially those with positive or close vaginal mucosal surgical margins), vaginal cylinder brachytherapy may be used as a boost to EBRT.**
- **SBRT is not considered an appropriate routine alternative to brachytherapy.**
- **Point A, representing a paracervical reference point, has been the most widely used, validated, and reproducible dosing parameter used to date. However, limitations of the Point A dosing system include the fact that it does not take into account the three-dimensional shape of tumors, nor individual tumor to normal tissue structure correlations. There are increasing efforts to use and standardize image-based volumetric brachytherapy approaches using MRI, CT, or ultrasound—international validation efforts are underway.<sup>4,5</sup>**

**Note: All recommendations are category 2A unless otherwise indicated.**

**Clinical Trials: NCCN believes that the best management of any patient with cancer is in a clinical trial. Participation in clinical trials is especially encouraged.**

[Continued](#)

**PRINCIPLES OF RADIATION THERAPY****Radiation Dosing Considerations**

- The most common historical dosing parameters for brachytherapy use a system that includes specifying the dose at point A and incorporates specific guidelines for “radioactive source loading and distribution of activity” within the uterus and vagina, based on anatomic considerations. Doses are also calculated at standardized point B and bladder and rectal points. Current efforts at 3-D image-guided brachytherapy seek to optimize implant dose coverage of the tumor, while potentially reducing the dose to adjacent bladder, rectum, and bowel structures.<sup>6</sup> Nonetheless, the weight of experience and tumor control results and the majority of continuing clinical practice have been based on the point A dosing system.<sup>7</sup> Attempts to improve dosing with image-guided brachytherapy should take care not to underdose tumors relative to the point A system dose recommendations.
- The point A dose recommendations provided in the NCCN Guidelines are based on traditional, and widely validated, dose fractionation and brachytherapy at low dose rates (LDRs). In these provided dose recommendations, for EBRT, the dose is delivered at 1.8 to 2.0 Gy per daily fraction. For brachytherapy, the dose at point A assumes an LDR delivery of 40 to 70 cGy/h. Clinicians using HDR brachytherapy would depend on the linear-quadratic model equation to convert nominal HDR dose to point A to a biologically equivalent LDR dose to point A (<http://www.americanbrachytherapy.org/guidelines/>). Multiple brachytherapy schemes have been used when combined with EBRT. However, one of the more common HDR approaches is 5 insertions with tandem and colpostats, each delivering 6 Gy nominal dose to point A. This scheme results in a nominal HDR point A dose of 30 Gy in 5 fractions, which is generally accepted to be the equivalent to 40 Gy to point A (tumor surrogate dose) using LDR brachytherapy.

[Continued](#)

**Note:** All recommendations are category 2A unless otherwise indicated.

**Clinical Trials:** NCCN believes that the best management of any patient with cancer is in a clinical trial. Participation in clinical trials is especially encouraged.

## PRINCIPLES OF RADIATION THERAPY

### Definitive Radiation Therapy for an Intact Cervix

- In patients with an intact cervix (ie, those who do not have surgery), the primary tumor and regional lymphatics at risk are typically treated with definitive EBRT to a dose of approximately 45 Gy (40–50 Gy). The volume of the EBRT would depend on the nodal status as determined surgically or radiographically (as previously described). The primary cervical tumor is then boosted, using brachytherapy, with an additional 30 to 40 Gy to point A (in LDR equivalent dose), for a total point A dose (as recommended in the guidelines) of 80 Gy (small-volume cervical tumors) to 85 Gy or greater (larger-volume cervical tumors). Grossly involved unresected nodes may be evaluated for boosting with an additional 10 to 15 Gy of highly conformal (and reduced volume) EBRT. With higher doses, especially of EBRT, care must be taken to exclude, or to severely limit, the volume of normal tissue included in the high-dose region(s) ([see Discussion](#)).

### Posthysterectomy Adjuvant Radiation Therapy

- Following primary hysterectomy, the presence of one or more pathologic risk factors may warrant the use of adjuvant radiotherapy. At a minimum, the following should be covered: upper 3 to 4 cm of the vaginal cuff, the parametria, and immediately adjacent nodal basins (such as the external and internal iliacs). For documented nodal metastasis, the superior border of the radiation field should be appropriately increased (as previously described). A dose of 45 to 50 Gy in standard fractionation is generally recommended. Grossly involved unresected nodes may be evaluated for boosting with an additional 10 to 15 Gy of highly conformal (and reduced volume) EBRT. With higher doses, especially of EBRT, care must be taken to exclude, or to severely limit, the volume of normal tissue included in the high-dose region(s) ([see Discussion](#)).

### Intraoperative Radiation Therapy

- IORT is a specialized technique that delivers a single, highly focused dose of radiation to a tumor bed at risk, or isolated unresectable residual, during an open surgical procedure.<sup>8</sup> It is particularly useful in patients with recurrent disease within a previously radiated volume. During IORT, overlying normal tissue (such as bowel or other viscera) can be manually displaced from the region at risk. IORT is typically delivered with electrons using pre-formed applicators of variable sizes (matched to the surgically defined region at risk), which further constrain the area and depth of radiation exposure to avoid surrounding normal structures.

**Note:** All recommendations are category 2A unless otherwise indicated.

**Clinical Trials:** NCCN believes that the best management of any patient with cancer is in a clinical trial. Participation in clinical trials is especially encouraged.

[Continued](#)

**PRINCIPLES OF RADIATION THERAPY**  
**(References)**

- <sup>1</sup>Klopp, AH, Yeung AR, Deshmukh S, et al.. A Phase III Randomized Trial Comparing Patient-Reported Toxicity and Quality of Life (QOL) During Pelvic Intensity Modulated Radiation Therapy as Compared to Conventional Radiation Therapy. *Int J Radiat Oncol Biol Phys* 2016;96:S3.
- <sup>2</sup>Choi CW, Cho CK, Yoo SY, et al. Image-guided stereotactic body radiation therapy in patients with isolated para-aortic lymph node metastases from uterine cervical and corpus cancer. *Int J Radiat Oncol Biol Phys* 2009;74:147–153.
- <sup>3</sup>Higginson DS, Morris DE, Jones EL, et al. Stereotactic body radiotherapy (SBRT): Technological innovation and application in gynecologic oncology. *Gynecol Oncol* 2011;120:404–412.
- <sup>4</sup>Haie-Meder C, R Potter, E Van Limbergen E, et al. Recommendations from Gynaecological (GYN) GEC-ESTRO Working Group (I): concepts and terms in 3D image based 3D treatment planning in cervix cancer brachytherapy with emphasis on MRI assessment of GTV and CTV. *Radiother Oncol* 2005. 74:235-245.
- <sup>5</sup>Pötter R, Georg P, Dimopoulos JC, et al. Clinical outcome of protocol based image (MRI) guided adaptive brachytherapy combined with 3D conformal radiotherapy with or without chemotherapy in patients with locally advanced cervical cancer. *Radiother Oncol* 2011; 100:116–123.
- <sup>6</sup>Pötter R, Haie-Meder C, Van Limbergen E, et al. Recommendations from gynaecological (GYN) GEC ESTRO working group (II): concepts and terms in 3D image-based treatment planning in cervix cancer brachytherapy-3D dose volume parameters and aspects of 3D image-based anatomy, radiation physics, radiobiology. *Radiother Oncol* 2006;78:67-77.
- <sup>7</sup>Viswanathan AN, Erickson BA. Three-dimensional imaging in gynecologic brachytherapy: a survey of the American Brachytherapy Society. *Int J Radiat Oncol Biol Phys* 2010;76:104-109.
- <sup>8</sup>del Carmen MG, McIntyre JF, Goodman A. The role of radiation therapy (IORT) in the treatment of locally advanced gynecologic malignancies. *Oncologist* 2000;5:18-25.

**Note: All recommendations are category 2A unless otherwise indicated.**

**Clinical Trials: NCCN believes that the best management of any patient with cancer is in a clinical trial. Participation in clinical trials is especially encouraged.**

**SEDLIS CRITERIA FOR EXTERNAL PELVIC RADIATION AFTER RADICAL HYSTERECTOMY IN NODE-NEGATIVE, MARGIN-NEGATIVE, PARAMETRIA-NEGATIVE CASES<sup>1,2,3,4</sup>**

LVSI	Stromal Invasion	Tumor Size (cm) (Determined by clinical palpation)
+	Deep 1/3	Any
+	Middle 1/3	≥2
+	Superficial 1/3	≥5
-	Middle or Deep 1/3	≥4

**LVSI: Lymphovascular space invasion**

<sup>1</sup>Modified with permission from Sedlis A, Bundy BN, Rotman MZ, et al. A randomized trial of pelvic radiation therapy versus no further therapy in selected patients with stage IB carcinoma of the cervix after radical hysterectomy and pelvic lymphadenectomy: a gynecologic oncology study group. *Gynecol Oncol* 1999;73:177-183.

<sup>2</sup>Delgado G, Bundy B, Zaino R, et al. Prospective surgical-pathological study of disease-free interval in patients with stage IB squamous cell carcinoma of the cervix: a gynecologic oncology group study. *Gynecol Oncol* 1990;38:352-357.

<sup>3</sup>Rotman M, Sedlis A, Piedmont MR, et al. A phase III randomized trial of postoperative pelvic irradiation in stage IB cervical carcinoma with poor prognostic features: follow-up of a gynecologic oncology group study. *Int J Radiat Oncol Biol Phys* 2006;65:169-176.

<sup>4</sup>Risk factors may not be limited to the Sedlis Criteria.

**Note: All recommendations are category 2A unless otherwise indicated.**

**Clinical Trials: NCCN believes that the best management of any patient with cancer is in a clinical trial. Participation in clinical trials is especially encouraged.**

**CHEMOTHERAPY REGIMENS FOR RECURRENT OR METASTATIC CERVICAL CANCER†**  
(Strongly consider clinical trial)

**First-line combination therapy††**

- Cisplatin/paclitaxel/bevacizumab<sup>1</sup> (category 1)
- Cisplatin/paclitaxel (category 1)<sup>2,3</sup>
- Topotecan/paclitaxel/bevacizumab<sup>1</sup> (category 1)
- Carboplatin/paclitaxel<sup>4,5</sup> (Category 1 for patients who have received prior cisplatin therapy)
- Carboplatin/paclitaxel/bevacizumab
- Cisplatin/topotecan<sup>6</sup>
- Topotecan/paclitaxel
- Cisplatin/gemcitabine (category 3)<sup>7</sup>

**Possible first-line single-agent therapy**

- Cisplatin (preferred as a single agent)<sup>3</sup>
- Carboplatin<sup>8</sup>
- Paclitaxel<sup>9</sup>

**Second-line therapy†††**

- (Agents listed are category 2B unless otherwise noted)
- Bevacizumab
  - Albumin-bound paclitaxel
  - Docetaxel
  - 5-FU (5-fluorouracil)
  - Gemcitabine
  - Ifosfamide
  - Irinotecan
  - Mitomycin
  - Pemetrexed
  - Topotecan
  - Vinorelbine

†Cisplatin, carboplatin, docetaxel, and paclitaxel may cause drug reactions ([See NCCN Guidelines for Ovarian Cancer--Management of Drug Reactions \[OV-C\]](#)).

††Cost and toxicity should be carefully considered when selecting an appropriate regimen for treatment.

†††References for second-line therapy are provided in the [Discussion](#).

**Note: All recommendations are category 2A unless otherwise indicated.**

**Clinical Trials: NCCN believes that the best management of any patient with cancer is in a clinical trial. Participation in clinical trials is especially encouraged.**

[Continued](#)

**CERV-E**  
**1 OF 2**



### **CHEMOTHERAPY REGIMENS FOR RECURRENT OR METASTATIC CERVICAL CANCER** **(References)**

- <sup>1</sup>Tewari KS1, Sill MW, Long HJ 3rd, et al. Improved survival with bevacizumab in advanced cervical cancer. N Engl J Med 2014 Feb 20;370(8):734-43.
- <sup>2</sup>Monk BJ, Sill MW, McMeekin DS, et al. Phase III trial of four cisplatin-containing doublet combinations in stage IVB, recurrent, or persistent cervical carcinoma: A Gynecologic Oncology Group Study. J Clin Oncol 2009;27:4649-4655.
- <sup>3</sup>Moore DH, Blessing JA, McQuellon RP, et al. Phase III study of cisplatin with or without paclitaxel in stage IVB, recurrent, or persistent squamous cell carcinoma of the cervix: a gynecologic oncology group study. J Clin Oncol 2004;22:3113-3119.
- <sup>4</sup>Moore KN, Herzog TJ, Lewin S, et al. A comparison of cisplatin/paclitaxel and carboplatin/paclitaxel in stage IVB, recurrent or persistent cervical cancer. Gynecol Oncol 2007;105:299-303.
- <sup>5</sup>Kitagawa R et al. Paclitaxel plus carboplatin versus paclitaxel plus cisplatin in metastatic or recurrent cervical cancer: the open-label randomized phase III trial JCOG0505. J Clin Oncol 2015;33:2129-2135.
- <sup>6</sup>Long HJ, 3rd, Bundy BN, Grendys EC, Jr., et al. Randomized phase III trial of cisplatin with or without topotecan in carcinoma of the uterine cervix: a Gynecologic Oncology Group Study. J Clin Oncol 2005;23:4626-4633.
- <sup>7</sup>Brewer CA, Blessing JA, Nagourney RA, et al. Cisplatin plus gemcitabine in previously treated squamous cell carcinoma of the cervix. Gynecol Oncol 2006;100:385-388.
- <sup>8</sup>Weiss GR, Green S, Hannigan EV, et al. A phase II trial of carboplatin for recurrent or metastatic squamous carcinoma of the uterine cervix: a Southwest Oncology Group study. Gynecol Oncol 1990;39:332-336.
- <sup>9</sup>Kudelka AP, Winn R, Edwards CL, et al. An update of a phase II study of paclitaxel in advanced or recurrent squamous cell cancer of the cervix. Anticancer Drugs 1997;8:657-661.

**Note: All recommendations are category 2A unless otherwise indicated.**

**Clinical Trials: NCCN believes that the best management of any patient with cancer is in a clinical trial. Participation in clinical trials is especially encouraged.**



**Table 1** AJCC Tumor-Node-Metastases (TNM) and International Federation of Gynecology and Obstetrics (FIGO) Surgical Staging Systems for Carcinoma of the Uterine Cervix

<b>TNM Categories</b>	<b>FIGO Stages</b>	<b>Surgical-Pathologic Findings</b>	<b>TNM Categories</b>	<b>FIGO Stages</b>	<b>Surgical-Pathologic Findings</b>
<b>TX</b>		Primary tumor cannot be assessed	<b>T2a</b>	<b>IIA</b>	Tumor without parametrial invasion
<b>T0</b>		No evidence of primary tumor	<b>T2a1</b>	<b>IIA1</b>	Clinically visible lesion 4.0 cm or less in greatest dimension
<b>Tis*</b>		Carcinoma in situ (preinvasive carcinoma)	<b>T2a2</b>	<b>IIA2</b>	Clinically visible lesion more than 4.0 cm in greatest dimension
<b>T1</b>	<b>I</b>	Cervical carcinoma confined to cervix (extension to corpus should be disregarded)	<b>T2b</b>	<b>IIB</b>	Tumor with parametrial invasion
<b>T1a**</b>	<b>IA</b>	Invasive carcinoma diagnosed only by microscopy. Stromal invasion with a maximum depth of 5.0 mm measured from the base of the epithelium and a horizontal spread of 7.0 mm or less. Vascular space involvement, venous or lymphatic, does not affect classification	<b>T3</b>	<b>III</b>	Tumor extends to pelvic wall and/or involves lower third of vagina and/or causes hydronephrosis or nonfunctioning kidney##
<b>T1a1</b>	<b>IA1</b>	Measured stromal invasion 3.0 mm or less in depth and 7.0 mm or less in horizontal spread	<b>T3a</b>	<b>IIIA</b>	Tumor involves lower third of vagina, no extension to pelvic wall
<b>T1a2</b>	<b>IA2</b>	Measured stromal invasion more than 3.0 mm and not more than 5.0 mm with a horizontal spread 7.0 mm or less	<b>T3b</b>	<b>IIIB</b>	Tumor extends to pelvic wall and/or causes hydronephrosis or nonfunctioning kidney
<b>T1b</b>	<b>IB</b>	Clinically visible lesion confined to the cervix or microscopic lesion greater than T1a/IA2#	<b>T4</b>	<b>IVA</b>	Tumor invades mucosa of bladder or rectum, and/or extends beyond true pelvis (bullous edema is not sufficient to classify a tumor as T4)
<b>T1b1</b>	<b>IB1</b>	Clinically visible lesion 4.0 cm or less in greatest dimension	*Note: FIGO no longer includes Stage 0 (Tis).		
<b>T1b2</b>	<b>IB2</b>	Clinically visible lesion more than 4.0 cm in greatest dimension	**Note: All macroscopically visible lesions—even with superficial invasion—are T1b/IB.		
<b>T2</b>	<b>II</b>	Cervical carcinoma invades beyond uterus but not to pelvic wall or to lower third of vagina	#All macroscopically visible lesions—even with superficial invasion—are allotted to stage IB carcinomas. Invasion is limited to a measured stromal invasion with a maximal depth of 5.00 mm and a horizontal extension of not >7.00 mm. Depth of invasion should not be >5.00 mm taken from the base of the epithelium of the original tissue—superficial or glandular. The depth of invasion should always be reported in mm, even in those cases with “early (minimal) stromal invasion” (~1 mm). The involvement of vascular/lymphatic spaces should not change the stage allotment.		
			##On rectal examination, there is no cancer-free space between the tumor and the pelvic wall. All cases with hydronephrosis or non-functioning kidney are included, unless they are known to be due to another cause.		

Used with the permission of the American Joint Committee on Cancer (AJCC), Chicago, Illinois. The original and primary source for this information is the AJCC Cancer Staging Manual, Seventh Edition (2010) published by Springer Science+Business Media, LLC (SBM). (For complete information and data supporting the staging tables, visit [www.springer.com](http://www.springer.com).) Any citation or quotation of this material must be credited to the AJCC as its primary source. The inclusion of this information herein does not authorize any reuse or further distribution without the expressed, written permission of Springer SBM, on behalf of the AJCC.

Reprinted from: Pecorelli S. Revised FIGO staging for carcinoma of the vulva, cervix and endometrium. FIGO Committee on Gynecologic Oncology. Int J Gynaecol Obstet 2009;105:103-104. Copyright 2009, with permission from International Federation of Gynecology and Obstetrics.

## Staging-Cervical Cancer

**Table 1-Continued** AJCC Tumor-Node-Metastases (TNM) and International Federation of Gynecology and Obstetrics (FIGO) Surgical Staging Systems for Carcinoma of the Uterine Cervix

### **Regional Lymph Nodes (N)**

<b>TNM</b>	<b>FIGO</b>	
<b>Categories</b>	<b>Stages</b>	
<b>NX</b>		Regional lymph nodes cannot be assessed
<b>N0</b>		No regional lymph node metastasis
<b>N1</b>		Regional lymph node metastasis

### **Distant Metastasis (M)**

<b>TNM</b>	<b>FIGO</b>	
<b>Categories</b>	<b>Stages</b>	
<b>M0</b>		No distant metastasis
<b>M1</b>	<b>IVB</b>	Distant metastasis (including peritoneal spread, involvement of supraclavicular, mediastinal, or paraaortic lymph nodes, lung, liver, or bone)

Used with the permission of the American Joint Committee on Cancer (AJCC), Chicago, Illinois. The original and primary source for this information is the AJCC Cancer Staging Manual, Seventh Edition (2010) published by Springer Science+Business Media, LLC (SBM). (For complete information and data supporting the staging tables, visit [www.springer.com](http://www.springer.com).) Any citation or quotation of this material must be credited to the AJCC as its primary source. The inclusion of this information herein does not authorize any reuse or further distribution without the expressed, written permission of Springer SBM, on behalf of the AJCC.

Reprinted from: Pecorelli S. Revised FIGO staging for carcinoma of the vulva, cervix and endometrium. FIGO Committee on Gynecologic Oncology. Int J Gynaecol Obstet 2009;105:103-104. Copyright 2009, with permission from International Federation of Gynecology and Obstetrics.



## Discussion

### NCCN Categories of Evidence and Consensus

**Category 1:** Based upon high-level evidence, there is uniform NCCN consensus that the intervention is appropriate.

**Category 2A:** Based upon lower-level evidence, there is uniform NCCN consensus that the intervention is appropriate.

**Category 2B:** Based upon lower-level evidence, there is NCCN consensus that the intervention is appropriate.

**Category 3:** Based upon any level of evidence, there is major NCCN disagreement that the intervention is appropriate.

**All recommendations are category 2A unless otherwise noted.**

## Table of Contents

Overview .....	MS-2
Literature Search Criteria and Guidelines Update Methodology .....	MS-2
Diagnosis and Workup.....	MS-3
Principles of Staging and Surgery.....	MS-4
Clinical Staging .....	MS-4
Surgical Staging.....	MS-4
Primary Treatment.....	MS-7
Important Phase III Clinical Trials Underpinning Treatment Recommendations .....	MS-7

Early-Stage Disease.....	MS-8
Advanced Disease .....	MS-11
Metastatic Disease .....	MS-12
Adjuvant Treatment.....	MS-12
Surveillance .....	MS-13
Therapy for Relapse .....	MS-14
Locoregional Therapy.....	MS-14
Therapy for Metastatic Disease .....	MS-15
Incidental Cervical Cancer .....	MS-18
Radiation Therapy.....	MS-19
Radiation Treatment Planning .....	MS-19
Normal Tissue Considerations.....	MS-20
Cervical Cancer and Pregnancy.....	MS-21
Summary .....	MS-21
References .....	MS-23

## Overview

An estimated 12,990 new cases of carcinoma of the uterine cervix (ie, cervical cancer) will be diagnosed in the United States in 2016, and 4120 people will die of the disease.<sup>1</sup> Cervical cancer rates are decreasing among women in the United States, although incidence remains high among Hispanic/Latino, Black, and Asian women.<sup>2-5</sup> However, cervical cancer is a major world health problem for women. The global yearly incidence of cervical cancer in 2012 was 528,000; the annual death rate was 266,000.<sup>6</sup> It is the fourth most common cancer in women worldwide,<sup>7,8</sup> with 85% of cases occurring in developing countries, where cervical cancer is a leading cause of cancer death in women.<sup>6,9</sup>

Persistent human papillomavirus (HPV) infection is the most important factor in the development of cervical cancer.<sup>10,11</sup> The incidence of cervical cancer appears to be related to the prevalence of HPV in the population. In countries with a high incidence of cervical cancer, the prevalence of chronic HPV is approximately 10% to 20%, whereas the prevalence in low-incidence countries is 5% to 10%.<sup>7</sup> Immunization against HPV prevents infection with the types of HPV against which the vaccine is designed and, thus, is expected to prevent specific HPV cancer in women.<sup>12-16</sup> Other epidemiologic risk factors associated with cervical cancer are a history of smoking, parity, oral contraceptive use, early age of onset of coitus, larger number of sexual partners, history of sexually transmitted disease, certain autoimmune diseases, and chronic immunosuppression.<sup>17,18</sup> Smoking cessation should be advised in current smokers, and former smokers should continue to avoid smoking (See the NCCN Guidelines for Smoking Cessation and <http://smokefree.gov/>).

Squamous cell carcinomas account for approximately 80% of all cervical cancers and adenocarcinoma accounts for approximately 20%. In developed countries, the substantial decline in incidence and mortality of squamous cell carcinoma of the cervix is presumed to be the result of effective screening, although racial, ethnic, and geographic disparities exist.<sup>2,3,19,20</sup> However, adenocarcinoma of the cervix has increased over the past 3 decades, probably because cervical cytologic screening methods are less effective for adenocarcinoma.<sup>21-24</sup> Screening methods using HPV testing may increase detection of adenocarcinoma. Vaccination with HPV vaccines may also decrease the incidence of both squamous cell carcinoma and adenocarcinoma.<sup>23,25</sup>

By definition, the NCCN Guidelines cannot incorporate all possible clinical variations and are not intended to replace good clinical judgment or individualization of treatments. “Many exceptions to the rule” were discussed among the members of the cervical cancer panel during the process of developing these guidelines.

## Literature Search Criteria and Guidelines Update Methodology

Prior to the update of this version of the NCCN Guidelines® for Cervical Cancer, an electronic search of the PubMed database was performed to obtain key literature in cervical cancer published between 04/01/2015 and 04/01/2016, using the following search terms: cervical cancer or cervical carcinoma or carcinoma of the cervix. The PubMed database was chosen as it remains the most widely used resource for medical literature and indexes only peer-reviewed biomedical literature.

The search results were narrowed by selecting studies in humans published in English. Results were confined to the following article types: Clinical Trial, Phase II; Clinical Trial, Phase III; Clinical Trial,

Phase IV; Guideline; Randomized Controlled Trial; Meta-Analysis; Systematic Reviews; and Validation Studies.

The PubMed search resulted in 71 citations and their potential relevance was examined. The data from key PubMed articles as well as articles from additional sources deemed as relevant to these Guidelines and discussed by the panel have been included in this version of the Discussion section (eg, e-publications ahead of print, meeting abstracts). Recommendations for which high-level evidence is lacking are based on the panel's review of lower-level evidence and expert opinion.

The complete details of the Development and Update of the NCCN Guidelines are available at [www.NCCN.org](http://www.NCCN.org).

## Diagnosis and Workup

These NCCN Guidelines discuss squamous cell carcinoma, adenosquamous carcinoma, and adenocarcinoma of the cervix. Neuroendocrine carcinoma, small cell tumors, glassy-cell carcinomas, sarcomas, and other histologic types are not within the scope of these guidelines.

Currently, the International Federation of Gynecology and Obstetrics (FIGO) evaluation procedures for staging are limited to colposcopy, biopsy, conization of the cervix, cystoscopy, and proctosigmoidoscopy. More complex radiologic and surgical staging procedures are not addressed in the FIGO classification. In the United States, however, CT, MRI, combined PET/CT, and surgical staging are often used to guide treatment options and design.<sup>26-30</sup>

The earliest stages of cervical carcinoma may be asymptomatic or associated with a watery vaginal discharge and postcoital bleeding or

intermittent spotting. Often these early symptoms are not recognized by the patient. Because of the accessibility of the uterine cervix, cervical cytology or Papanicolaou (Pap) smears and cervical biopsies can usually result in an accurate diagnosis. Cone biopsy (ie, conization) is recommended if the cervical biopsy is inadequate to define invasiveness or if accurate assessment of microinvasive disease is required. However, cervical cytologic screening methods are less useful for diagnosing adenocarcinoma, because adenocarcinoma in situ affects areas of the cervix that are harder to sample (ie, endocervical canal).<sup>5,24</sup> The College of American Pathologists (CAP) protocol for cervical carcinoma is a useful guide ([http://www.cap.org/apps/docs/committees/cancer/cancer\\_protocols/2012/Cervix\\_12protocol.pdf](http://www.cap.org/apps/docs/committees/cancer/cancer_protocols/2012/Cervix_12protocol.pdf)). This CAP protocol was revised in June 2012 and reflects recent updates in the AJCC/FIGO staging (ie, AJCC Cancer Staging Manual, 7<sup>th</sup> edition).

Workup for these patients with suspicious symptoms includes history and physical examination, complete blood count (CBC) (including platelets), and liver and renal function tests. Recommended radiologic imaging includes chest radiograph, CT, or combined PET/CT, and MRI as indicated (eg, to rule out disease high in the endocervix).<sup>27,31</sup> For detailed imaging recommendations by stage and planned treatment approach, see *Principles of Imaging* in the NCCN Guidelines for Cervical Cancer). Cystoscopy and proctoscopy are only recommended if bladder or rectal extension is suspected. The panel had major disagreement whether physicians should consider HIV (human immunodeficiency virus) testing as part of a patient's initial workup; this recommendation is included as a category 3.



## Principles of Staging and Surgery

### Clinical Staging

Because noninvasive radiographic imaging may not be routinely available in low-resource countries, the FIGO system limits the imaging to chest radiography, intravenous pyelography, and barium enema. The staging of carcinoma of the cervix is largely a clinical evaluation. Although surgical staging is more accurate than clinical staging, surgical staging often cannot be performed in low-resource countries.<sup>29,32,33</sup> The panel currently uses the 2009 FIGO definitions and staging system (see Table 1).<sup>32,34</sup> FIGO directly aligns with AJCC staging with the exception of stage 0, which does not exist in the FIGO system.<sup>35,36</sup> Additionally, regional nodal metastasis is not included in the FIGO staging criteria. With the 2009 FIGO staging, stage IIA is now subdivided into stage IIA1 (tumor size  $\leq 4$  cm) and stage IIA2 (tumor size  $>4$  cm), which is the only change from the previous 1994 FIGO staging system.

Importantly, lymphovascular space invasion (LVSI) does not alter the FIGO classification.<sup>32</sup> FIGO did not include LVSI because pathologists do not always agree on whether LVSI is present in tissue samples. Some panel members believe that patients with stage IA1 who have extensive LVSI should be treated using stage IB1 guidelines.

The use of MRI, CT, or combined PET/CT scans may aid in treatment planning, but it is not accepted for formal staging purposes.<sup>31,33,37</sup> In addition, FIGO has always maintained that staging is intended for comparison purposes only and not as a guide for therapy. As a result, the panel uses the FIGO definitions as the stratification system for these guidelines, although the findings on imaging studies (ie, CT, MRI, and PET/CT) are used to guide treatment options and design. MRI is useful to delineate disease extent and to guide decisions regarding fertility-

sparing versus non-fertility-sparing treatment approaches<sup>38-44</sup>; while PET/CT may be useful to detect and/or rule out metastasis.<sup>45-48</sup>

### Surgical Staging

#### **Conservative/Fertility-Sparing Approaches**

Fertility-sparing approaches may be considered in highly selected patients who have been thoroughly counseled regarding disease risk as well as prenatal and perinatal issues.<sup>49</sup>

Microinvasive disease (FIGO stage IA-1 with no LVSI) is associated with an extremely low incidence of lymphatic metastasis,<sup>50-53</sup> and conservative treatment with conization is an option (category 2A) for individuals with no evidence of LVSI. In stage IA1 individuals with evidence of LVSI, a reasonable conservative approach is conization (with negative margins) in addition to SLN mapping algorithm or pelvic lymphadenectomy.

The goal of conization is *en bloc* removal of the ectocervix and endocervical canal; the shape of the cone can be tailored to the size, type, and location of the lesion (ie, narrow, long cone in cases of suspected invasive adenocarcinoma). The panel recommends cold knife conization as the preferred approach to conization. However, LEEP (loop electrosurgical excision procedure) is acceptable as long as adequate margins, proper orientation, and a non-fragmented specimen without electrosurgical artifact can be obtained.<sup>54-59</sup> Endocervical curettage may be added as clinically indicated.

Select patients with stage IA-2 or IB1 cervical cancer, especially for those with tumors of less than 2 cm in diameter, may be eligible for conservative surgery.<sup>60,61</sup> Radical trachelectomy may offer a reasonable fertility-sparing treatment option for patients with stage IA-2 or IB-1 cervical cancer with lesions that are less than or equal to 2 cm in

diameter.<sup>62-64</sup> In a radical trachelectomy, the cervix, vaginal margins, and supporting ligaments are removed while leaving the main body and fundus of the uterus intact.<sup>65</sup> Laparoscopic pelvic lymphadenectomy accompanies the procedure and can be performed with or without SLN mapping (see *Lymph Node Mapping and Dissection* below). Due to their aggressive nature, tumors of small cell neuroendocrine histology are considered inappropriate for radical trachelectomy.<sup>66</sup> Trachelectomy is also inappropriate for treating gastric type cervical adenocarcinoma and adenoma malignum (minimal deviation adenocarcinoma) due to their diagnostic challenges and potentially aggressive nature.<sup>67</sup>

Vaginal radical trachelectomy (VRT) may be used for carefully selected patients with lesions of 2 cm diameter or less.<sup>68-70</sup> Abdominal radical trachelectomy (ART) provides a broader resection of the parametria,<sup>62,70</sup> than the vaginal approach and is commonly used in stage IB1 lesions. Multiple case series have evaluated safety and outcomes with vaginal vs. abdominal approaches to radical trachelectomy,<sup>68,71-73</sup> including systematic reviews on VRT<sup>74</sup> and ART.<sup>75</sup> A limited number of studies have specifically examined this approach in patients with larger stage IB1 tumors between 2 cm and 4 cm in diameter and reported safe oncologic outcomes, but as expected, more patients in this subgroup will require adjuvant therapy that may reduce fertility.<sup>76-78</sup>

Studies that examined pregnancy in women who underwent radical trachelectomy have provided differing success rates. One case series of 125 patients with cervical cancer who underwent VRT reported 106 pregnancies among 58 women.<sup>69</sup> In a systematic review of 413 women who underwent ART, 113 women attempted pregnancy and 67 (59%) successfully conceived.<sup>72</sup> However, miscarriage and pre-term labor rates were elevated among women who underwent radical trachelectomy.<sup>69,79-81</sup>

### ***Non-Fertility-Sparing Approaches***

The Querleu and Morrow surgical classification system<sup>82,83</sup> describes the degree of resection and nerve preservation for radical hysterectomy in three-dimensional planes and updates the previously used Piver-Rutledge classifications.<sup>84</sup> Approaches to hysterectomy include simple/extrafascial hysterectomy (Type A), modified radical hysterectomy (Type B), and radical hysterectomy (Type C).<sup>85,86</sup>

For patients with IA-1 disease, cone excision, simple/extrafascial hysterectomy, and modified radical hysterectomy are options. Radical hysterectomy with bilateral pelvic lymph node dissection (with or without SLN mapping) is the preferred treatment approach for patients with FIGO stage IA-2 through IIA1 cervical cancers. Radical hysterectomy is preferred over simple hysterectomy due to its wider paracervix margin of resection that also includes aspects of the cardinal and uterosacral ligaments, upper vagina, pelvic nodes, and at times, para-aortic nodes. In the United States, definitive chemoradiation is typically preferred over radical surgery for select patients with bulky FIGO IB2 lesions and the vast majority of FIGO stage IIA2 or greater cervical cancers. Abroad, select FIGO IB2-IIB cases may be treated with radical hysterectomy or neoadjuvant chemotherapy followed by radical hysterectomy.

For recurrent or persistent cervical cancers that are confined to the central pelvis (ie, no distant metastasis), pelvic exenteration may be a potentially curative surgical option.<sup>87,88</sup> Discussion of the various approaches to pelvic exenteration are offered by Chi and colleagues,<sup>85</sup> and in the GOG Surgical Manual.<sup>86</sup>



## ***Lymph Node Mapping and Dissection***

### ***Sentinel Lymph Node Mapping***

Recent data suggest that SLN biopsy may be useful for decreasing the need for pelvic lymphadenectomy in patients with early-stage cervical cancer.<sup>89,90</sup>

Prospective studies generally support the feasibility of SLN detection in patients with early-stage cervical cancer and suggest that extensive pelvic lymph node dissection may be safely avoided in a significant proportion of early-stage cases.<sup>89-100</sup>

Meta-analyses of pooled data from SLN mapping studies have generated SLN detection rates of 89-92% and sensitivity of 89% to 90%.<sup>101,102</sup> Factors determined to be important for detection included laparoscopy, dual blue dye/ radiocolloid tracer approaches, and pathologic assessment using immunohistochemistry. However, based on a recent metaanalysis, indocyanine green tracer appears to provide similar overall and bilateral detection rates to the standard dual blue dye/ technetium-99 approach.<sup>103</sup>

However, study data also highlight limited sensitivity of this approach and potential to miss SLN micrometastases and isolated tumor cells using intraoperative assessment (ie, frozen section or imprint cytology).<sup>92,96,98</sup> The sensitivity of this approach appears to be better in patients with tumors equal to or less than 2 cm in diameter.<sup>89,91,93,104</sup> Ultrastaging of detected SLNs has been shown to provide enhanced detection of micrometastases.<sup>94,95</sup>

The SENTICOL longitudinal study demonstrated the utility of SLN mapping to uncover unusual lymph drainage patterns.<sup>93,105</sup> It also highlighted limited agreement between lymphoscintigraphy and intraoperative SLN mapping.<sup>105</sup> Additionally, this study revealed that

bilateral SLN detection and biopsy provided a more reliable assessment of sentinel nodal metastases and led to fewer false negatives than unilateral SLN biopsy.<sup>90</sup> Generally, research supports ipsilateral lymphadenectomy if no sentinel nodes are detected on a given side of the pelvis as outlined in the SLN mapping algorithm.<sup>89,90,106</sup>

Based on these collective data, the panel recommends consideration of SLN mapping algorithm and emphasizes that best detection and mapping results are in tumors of less than 2 cm diameter. Adherence to the SLN mapping algorithm is important; surgeons should perform side-specific nodal dissection in any cases of failed mapping and remove all suspicious or grossly enlarged nodes regardless of SLN mapping.<sup>89</sup>

### ***Para-Aortic Lymph Node Assessment***

Studies of the incidence and distribution of lymph node metastases in women with stage IB to IIB cervical cancers suggest that para-aortic lymph node involvement is closely tied to the presence of pelvic lymph node metastases, larger primary tumor size (>2cm), and metastasis to the common iliac nodes.<sup>107,108</sup>

Analysis of outcomes data from 555 women who participated in Gynecologic Oncology Group (GOG) trials (GOG 85, GOG 120, and GOG 165) revealed a more positive prognosis for patients who underwent surgical exclusion of para-aortic lymph node involvement versus those who underwent radiographic determination of para-aortic node involvement.<sup>29</sup> One study examined the efficacy of extending the radiation therapy (RT) field to the para-aortic region in patients with para-aortic lymph node involvement, and showed therapeutic benefit especially in patients with small-volume nodal disease.<sup>109</sup> A randomized controlled trial examining surgical versus radiologic staging and treatment of para-aortic lymph node involvement is ongoing.<sup>110</sup>

The panel includes para-aortic lymph node sampling (category 2B) as an option during pelvic lymph node dissection.

### **Minimally Invasive Surgical Approaches**

Panel members discussed whether laparoscopic and robotic approaches should be recommended for staging and treatment. These techniques are being used more frequently and have been found to be therapeutically feasible and beneficial when performed by appropriately-trained and experienced surgeons.<sup>111,112</sup> Potential advantages associated with laparoscopic and robotic approaches include decreased hospital stay and more rapid patient recovery.<sup>113-116</sup>

Laparoscopic staging, lymphadenectomies, and radical hysterectomies can be performed satisfactorily and are used routinely in selected patients in several NCCN Member Institutions.<sup>117-120</sup> Data suggest that oncologic outcomes following laparoscopic radical hysterectomy are comparable to abdominal approaches after 3 to 6 years of follow-up.<sup>116,121-123</sup>

Robotic radical hysterectomy (which is another minimally invasive surgical technique) is currently being performed for patients with early-stage cervical cancer. A recent systematic review and meta-analysis of data from 26 studies found that laparoscopic and robotic radical hysterectomy approaches appeared to provide equivalent intraoperative and short-term postoperative outcomes.<sup>124</sup> Robotic radical hysterectomy has been associated with less blood loss, shorter hospital stay, and wound-related complications compared with open abdominal approaches.<sup>124-126</sup> Additional recent studies have shown comparable oncologic outcomes (disease recurrence and survival rates) for abdominal and robotic radical hysterectomy after 3 to 5 years followup.<sup>116,127,128</sup>

The ongoing randomized phase III LACC trial (NCT00614211) seeks to provide definitive comparison of outcomes data in more than 700 patients undergoing open radical abdominal hysterectomy, or total laparoscopic radical hysterectomy/total robotic radical hysterectomy.

### **Primary Treatment**

The primary treatment of early-stage cervical cancer is either surgery or RT. Surgery is typically reserved for early-stage disease, fertility-preservation, and smaller lesions, such as stage IA, IB1, and selected IIA1.<sup>28</sup> The panel agrees that concurrent chemoradiation is generally the primary treatment of choice for stages IB2 to IVA disease based on the results of 5 randomized clinical trials (see Table 2).<sup>129,130</sup>

Chemoradiation can also be used for patients who are not candidates for hysterectomy. Although few studies have assessed treatment specifically for adenocarcinomas, they are typically treated in a similar manner to squamous cell carcinomas.<sup>131-133</sup>

Pelvic RT or chemoradiation will invariably lead to ovarian failure in premenopausal women.<sup>134</sup> To preserve intrinsic hormonal function, ovarian transposition may be considered before pelvic RT for select women younger than 45 years of age with squamous cell cancers.<sup>135,136</sup>

### **Important Phase III Clinical Trials Underpinning Treatment Recommendations**

A randomized Italian study compared RT alone versus radical hysterectomy and lymph node dissection in patients with clinical early-stage disease (stage IB–IIA).<sup>137</sup> Adjuvant RT was given to those with parametrial extension, less than 3 cm of uninvolved cervical stroma, positive margins, or positive nodes. Identical outcomes were noted for patients treated with radiation versus surgery, with (or without) postoperative radiation, but higher complication rates were noted for the combined modality approach.

Concurrent chemoradiation, using cisplatin-based chemotherapy (either cisplatin alone or cisplatin/5-FU), is the treatment of choice for stages IB2, II, III, and IVA disease based on the results of 5 randomized clinical trials (see Table 2).<sup>138-143</sup> These 5 trials have shown that the use of concurrent chemoradiation results in a 30% to 50% decrease in the risk of death compared with RT alone. Although the optimal concurrent chemotherapy regimen to use with RT requires further investigation, these 5 trials clearly established a role for concurrent cisplatin-based chemoradiation. Based on these data, the NCI issued an alert stating that strong consideration should be given to using chemoradiation instead of RT alone for invasive cervical cancer.<sup>143</sup> Long-term follow-up of 3 of these trials has confirmed that concurrent cisplatin-based chemoradiation improves progression-free survival (PFS) and overall survival when compared with RT with (or without) hydroxyurea.<sup>144-146</sup> A recent meta-analysis reported that chemoradiotherapy leads to a 6% improvement in 5-year survival (hazard ratio, 0.81;  $P < .001$ ).<sup>147</sup> A large, population-based registry analysis in Canada (n=4069) confirmed that chemoradiotherapy improved outcomes when compared with RT alone.<sup>148</sup>

Although chemoradiation is tolerated, acute and long-term side effects have been reported.<sup>147,149,150</sup> Some oncologists prefer concurrent single-agent cisplatin chemoradiation over cisplatin plus 5-FU chemoradiation, because the latter may be more toxic.<sup>130,151</sup> Concurrent carboplatin or nonplatinum chemoradiation regimens are options for patients who may not tolerate cisplatin-containing chemoradiation.<sup>147,152-156</sup> Note that when concurrent chemoradiation is used, the chemotherapy is typically given when the external-beam pelvic radiation is administered.<sup>130</sup> The panel believes that using “systemic consolidation” (ie, adding chemotherapy after chemoradiation) should

only be used in clinical trials (eg, OUTBACK [ANZGOG-0902/GOG 274, NCT01414608] and RTOG 724 [NCT00980954]).<sup>157</sup>

### **Early-Stage Disease**

After careful clinical evaluation and staging, the primary treatment of early-stage cervical cancer is either surgery or RT. The treatment schema is stratified using the FIGO staging system (see Table 1). A new fertility-sparing algorithm was added in 2012 for select patients with stage IA and IB1 disease (see *Primary Treatment (Fertility Sparing)* in the NCCN Guidelines for Cervical Cancer). Fertility-sparing surgery is generally not recommended for patients with small cell neuroendocrine tumors, gastric type adenocarcinoma, or adenoma malignum (minimal deviation adenocarcinoma) because of high-risk nature and a paucity of data.

#### **Stage IA1 Disease**

Recommended options for stage IA1 disease depend on the results of cone biopsy and whether patients 1) want to preserve their fertility; 2) are medically operable; or 3) have LVSI [see *Primary Treatment (Fertility Sparing)* and *Primary Treatment (Non-Fertility Sparing)* in the NCCN Guidelines for Cervical Cancer]. The extent of the lymph node dissection depends on whether pelvic nodal disease and/or LVSI are present and the size of the tumors. SLN mapping can be considered.

#### **Fertility-Sparing**

For patients who desire fertility preservation, cone biopsy with or without pelvic lymph node dissection is recommended.<sup>100,158,159</sup>

The goal of cone biopsy is margins that are negative for invasive disease and high-grade squamous intraepithelial lesion (HSIL). For patients with negative margins after cone biopsy and no findings of LVSI, observation may be an option if fertility preservation is desired.

For patients with positive margins after cone biopsy, options include repeat cone biopsy to better evaluate depth of invasion or a radical trachelectomy. In studies of patients who had positive margins after conization, predictors of residual disease included positive endocervical curettage, combined endocervical margin and endocervical curettage, and volume of disease.<sup>160-162</sup>

For patients with stage IA-1 disease with LVSI, conization (with negative margins) plus laparoscopic pelvic SLN mapping/lymphadenectomy is a reasonable strategy. In addition, these patients may also be treated with a radical trachelectomy and SLN mapping/pelvic lymph node dissection with (or without) para-aortic lymph node sampling (category 2B for elective para-aortic lymph node sampling) [see *Primary Treatment (Fertility Sparing)* in the NCCN Guidelines for Cervical Cancer].<sup>73,163-166</sup>

After childbearing is complete, hysterectomy can be considered for patients who have had either radical trachelectomy or a cone biopsy for early-stage disease if they have chronic, persistent HPV infection, they have persistent abnormal Pap tests, or they desire this surgery.

For young (<45 years) premenopausal women with early-stage squamous cell carcinoma who opt for ovarian preservation (ie, hysterectomy only), the rate of ovarian metastases is low.<sup>167,168</sup>

#### *Non–Fertility-Sparing*

For medically and technically operable patients with stage IA1 disease who do not desire fertility preservation, extrafascial (ie, simple) hysterectomy is commonly recommended for patients without LVSI and with either negative margins after cone biopsy or with positive margins for dysplasia. For patients with positive margins for carcinoma, modified radical hysterectomy is recommended with SLN mapping/pelvic lymph node dissection (category 2B for node dissection). SLN mapping can be

considered. Physicians can also consider repeat cone biopsy to better evaluate depth of invasion. If LVSI is present, then modified radical hysterectomy with SLN mapping/lymph node dissection is recommended (category 2B for elective para-aortic lymph node sampling only). Para-aortic node dissection is indicated for patients with known or suspected pelvic nodal disease. For patients with negative margins after cone biopsy, observation is recommended for those who are medically inoperable or those who refuse surgery.

#### **Stage IA2 Disease**

Recommendations for stage IA2 depend upon whether a patient wishes to preserve her fertility and if the disease is medically operable.

#### *Fertility-Sparing*

For patients who wish to preserve their fertility, radical trachelectomy and pelvic lymph node dissection with (or without) para-aortic lymph node sampling (category 2B for para-aortic node sampling) is recommended. SLN mapping can also be considered. Cone biopsy followed by observation is another option if the margins are negative and pelvic lymph node dissection is negative.

#### *Non–Fertility-Sparing*

For medically operable patients who do not desire fertility preservation, recommended treatment includes either surgery or RT (see *Primary Treatment (Non–Fertility Sparing)* in the NCCN Guidelines for Cervical Cancer). The recommended surgical option is radical hysterectomy and bilateral pelvic lymph node dissection with (or without) para-aortic lymph node sampling (category 2B for para-aortic node sampling). SLN mapping can also be considered. Para-aortic node dissection is indicated for patients with known or suspected pelvic nodal disease. Less radical surgical approaches for patients with stage IA2 disease are the subject of ongoing investigation.<sup>162,169</sup>



Pelvic external beam radiation (EBRT) with brachytherapy (traditionally 70-80 Gy to total point A dose) is a treatment option for patients who are medically inoperable or who refuse surgery.<sup>170</sup> These doses are recommended for most patients based on summation of conventional external-beam fractionation and low-dose-rate (40–70 cGy/h) brachytherapy equivalents. Treatment should be modified based on normal tissue tolerance, fractionation, and size of target volume or on biologic equivalence calculations when using high-dose-rate brachytherapy (see also the *Radiation Therapy* section in this Discussion).

#### **Stage IB and IIA Disease**

Depending on their stage and disease bulk, patients with stage IB or IIA tumors can be treated with surgery, RT, or concurrent chemoradiation. Fertility-sparing surgery is only recommended for select patients with stage IB1 disease (see next section). A combined PET/CT scan can be performed to rule out extrapelvic disease before deciding how to treat these patients. The GOG considers that surgical staging is an option for patients with advanced cervical cancer. Radiologic imaging is recommended for assessing stage IB2 and IIA2 tumors (see *Principles of Imaging* in the NCCN Guidelines for Cervical Cancer).

#### **Stage IB1: Fertility-Sparing**

For patients who desire fertility preservation, radical trachelectomy and pelvic lymph node dissection with (or without) para-aortic lymph node sampling is an option for stage IB1 disease, but typically only for tumors 2 cm or less [see *Primary Treatment (Fertility Sparing)* in the NCCN Guidelines for Cervical Cancer].<sup>62,163-166,171</sup> SLN mapping can also be considered. Tumors that are 2 to 4 cm have to be carefully selected for a fertility sparing approach as many of these patients may require postoperative adjuvant therapy due to pathologic risk factors (eg, Sedlis criteria or positive nodes). However, some surgeons suggest that a

2-cm cutoff may be used for vaginal trachelectomy, whereas a 4-cm cutoff may be used for abdominal (eg, laparotomy, laparoscopic, robotic) trachelectomy.<sup>172</sup> In one study, oncologic outcomes were similar after 4 years when comparing radical trachelectomy with radical hysterectomy for patients with stage IB1 cervical carcinoma.<sup>62</sup> Stage IB1 small cell neuroendocrine histology, gastric type adenocarcinoma, and adenoma malignum are not considered suitable for fertility-sparing surgery.

#### **Stage IB and IIA: Non-Fertility-Sparing**

Primary surgery consists of radical hysterectomy plus bilateral pelvic lymph node dissection with (or without) para-aortic lymph node sampling (category 1 for primary surgery).<sup>137,173</sup> SLN mapping can also be considered for stages IB1 and IIA1. Panel members feel that surgery is the most appropriate option for patients with stage IB1 or IIA1 disease, whereas concurrent chemoradiation is the most appropriate option for those with stage IB2 or IIA2 disease based on randomized trials.<sup>137-139,141,142</sup> Thus, the surgical option is category 1 for patients with stage IB1 or IIA1 disease; however, surgery is category 2B for those with stage IB2 or IIA2 disease.<sup>137</sup> Para-aortic node dissection may be performed for patients with larger tumors and suspected or known pelvic nodal disease. Some panel members feel that a pelvic lymph node dissection should be performed first and if negative, then the radical hysterectomy should be performed. If the lymph nodes are positive, then the hysterectomy should be abandoned; these patients should undergo chemoradiation. For patients with stage IB or IIA tumors (including those who are not candidates for hysterectomy), another option is combined pelvic EBRT and brachytherapy with (or without) concurrent cisplatin-containing chemotherapy [see *Primary Treatment (Non-Fertility Sparing)* in the NCCN Guidelines for Cervical Cancer]. Although concurrent chemoradiation has been proven effective in the

definitive treatment of more advanced-stage disease, this approach has not been specifically studied in patients with stage IB1 or IIA1 disease. Careful consideration of the risk/benefit ratio should be undertaken in these patients with smaller tumors.

For patients with clinical stage IB2 or IIA2 tumors who are treated with definitive radiation, concurrent cisplatin-containing chemotherapy has been shown to significantly improve patient survival. The panel recommends definitive EBRT with concurrent cisplatin-containing chemotherapy and brachytherapy (traditionally 75-80 Gy to total point A dose). Again, treatment should be modified based on normal tissue tolerance, fractionation, and size of target volume. Primary chemoradiation has a category 1 recommendation [see *Primary Treatment (Non-Fertility Sparing)* in the NCCN Guidelines for Cervical Cancer].<sup>138,139</sup>

For stage IB2 or IIA2 tumors, the panel had a major disagreement about recommending adjuvant hysterectomy (category 3) (also known as completion surgery) after primary chemoradiation.<sup>138</sup> Adjuvant hysterectomy after RT has been shown to improve pelvic control, but not overall survival, and is associated with increased morbidity.<sup>174</sup> A recent Cochrane review examined whether the addition of hysterectomy to standard non-surgical treatments benefitted women with locally advanced cervical cancer, finding insufficient data to demonstrate a survival benefit associated with surgery.<sup>175</sup> The morbidity is higher after completion surgery, but this may be reduced using a laparoscopic technique.<sup>176-179</sup> While routine completion hysterectomy is not typically performed, this approach may be considered in patients whose extent of disease or uterine anatomy precludes adequate coverage by brachytherapy.

### Advanced Disease

This category has traditionally included patients with stage IIB to IVA disease (ie, locally advanced disease). However, many oncologists now include patients with IB2 and IIA2 disease in the advanced disease category. For patients with more advanced tumors who are undergoing primary chemoradiation, the volume of RT is critical and guided by assessment of nodal involvement in the pelvic and para-aortic nodes. Radiologic imaging studies (including PET/CT) are recommended for stage IB2 or greater disease, especially for evaluation of nodal or extrapelvic tumor (see *Principles of Imaging* in the NCCN Guidelines for Cervical Cancer). MRI is useful to describe local disease extent and assist in radiation treatment planning. However, needle biopsy of extrauterine abnormality can be considered for questionable imaging findings. Surgical staging (ie, extraperitoneal or laparoscopic lymph node dissection) is also an option (category 2B) for these patients.<sup>180</sup> Surgical staging may also detect microscopic nodal disease that is not discernable with radiologic imaging.<sup>181</sup>

For patients without nodal disease or with disease limited to the pelvis only through surgical staging, treatment consists of pelvic EBRT with concurrent cisplatin-based chemotherapy and brachytherapy (category 1).<sup>129,130,139,141-143,182</sup> Currently, acceptable, concurrent, cisplatin-based regimens include either weekly cisplatin or the combination of cisplatin/5-FU given every 3 to 4 weeks during RT. An international phase III randomized trial reported that concurrent cisplatin/gemcitabine and EBRT followed by 2 additional cycles of cisplatin/gemcitabine after RT improved PFS and overall survival when compared with a standard regimen of concurrent cisplatin with pelvic EBRT.<sup>183</sup> However, this trial is controversial because of changes in its statistical design and because the reported superior regimen of concurrent cisplatin/gemcitabine and EBRT has unresolved toxicity issues.<sup>183-186</sup>

However, for patients with positive para-aortic and pelvic lymph nodes by imaging, imaging workup for metastatic disease is recommended. Extraperitoneal lymph node dissection should be considered followed by extended-field EBRT, concurrent cisplatin-containing chemotherapy, and brachytherapy (see *Primary Treatment* in the NCCN Guidelines for Cervical Cancer). Patients with positive para-aortic lymph nodes who are positive for distant metastases are treated with systemic chemotherapy (see *Chemotherapy Regimens for Recurrent or Metastatic Cervical Cancer* in the NCCN Guidelines) with (or without) individualized EBRT.<sup>187</sup>

### Metastatic Disease

For patients who present with distant metastatic disease (ie, stage IVB), primary treatment is often cisplatin-based chemotherapy (see *Therapy for Metastatic Disease* in this Discussion). In these situations, individualized EBRT may be considered for control of pelvic disease and other symptoms.<sup>187</sup>

### Adjuvant Treatment

Adjuvant treatment is indicated after radical hysterectomy depending on surgical findings and disease stage. Observation is appropriate for patients with stage IA2, IB1, or IIA1 disease who have negative nodes, negative margins, negative parametria, and no cervical risk factors after radical hysterectomy (Sedlis Criteria). However, adjuvant treatment is indicated after radical hysterectomy if pathologic risk factors are discovered.

Pelvic EBRT is recommended (category 1) with (or without) concurrent cisplatin-based chemotherapy (category 2B for chemotherapy) for patients with stage IA2, IB1, or IIA1 disease who have *negative* lymph nodes after surgery but have large primary tumors, deep stromal

invasion, and/or LVSI (see *Adjuvant Treatment* in the NCCN Guidelines for Cervical Cancer, Sedlis Criteria).<sup>188-192</sup>

Adjuvant pelvic RT alone versus no further therapy was tested in a randomized trial (GOG 92) of selected patients with node-negative stage IB carcinoma of the cervix after hysterectomy and pelvic lymphadenectomy.<sup>192</sup> Patients were considered to have “intermediate-risk” disease and were eligible for this trial if they had at least 2 of the following risk factors (commonly referred to as “Sedlis Criteria”): 1) greater than one-third stromal invasion; 2) capillary lymphatic space involvement; or 3) cervical tumor diameters more than 4 cm. Patients with positive lymph nodes or involved surgical margins were excluded. At 2 years, the recurrence-free rates were 88% for adjuvant RT versus 79% for the no-adjuvant-treatment group. After long-term follow-up (12 years), an updated analysis confirmed that adjuvant pelvic RT increased PFS; a clear trend towards improved overall survival was noted ( $P = .07$ ).<sup>188</sup> The role of concurrent cisplatin/RT in patients with intermediate-risk disease is currently being evaluated in an international phase III randomized trial (GOG 263, NCT01101451).

Potentially important risk factors for recurrence may not be limited to the “Sedlis Criteria” (ie, > one-third stromal invasion, LVSI, tumor size). Additional risk factors for consideration include tumor histology (eg, adenocarcinoma component)<sup>193,194</sup> and close or positive surgical margins.<sup>160,195</sup> A recent study has identified a “four-factor model” of intermediate risk factors that was predictive of recurrence in a cohort of 2158 patients with stage IB to IIA cervical cancers; predictive risk factors identified included tumor size  $\geq 3$  cm, deep stromal invasion of the outer third of the cervix, LVSI, and adenocarcinoma or adenosquamous carcinoma histology.<sup>193</sup> Among these patients, presence of any 2 factors was useful for predicting recurrence after radical hysterectomy.

Postoperative pelvic EBRT with concurrent cisplatin-containing chemotherapy (category 1)<sup>140</sup> with (or without) vaginal brachytherapy is recommended for patients with positive pelvic nodes, positive surgical margin, and/or positive parametrium; these patients are considered to have “high-risk” disease (see *Adjuvant Treatment* in the NCCN Guidelines for Cervical Cancer). Vaginal brachytherapy may be a useful boost for those with positive vaginal mucosal margins. Adjuvant concurrent chemoradiation significantly improves overall survival for patients with high-risk, early-stage disease (those with positive pelvic nodes, parametrial extension, and/or positive margins) who undergo radical hysterectomy and pelvic lymphadenectomy.<sup>140</sup> The Intergroup trial 0107/GOG 109 showed a statistically significant benefit of adjuvant pelvic radiation with concurrent cisplatin and 5-FU in the treatment of patients with stage IA2, IB, or IIA disease who had positive lymph nodes, positive margins, and/or microscopic parametrial involvement found at surgery.<sup>140</sup> A recent study re-evaluated these findings from GOG 109 in a population-based cohort (n = 3053) in the National Cancer Database, confirming the survival benefit of adjuvant chemoradiation but suggesting that this benefit may be best realized in patients with lymph node involvement.<sup>196</sup>

Depending on the results of primary surgery, imaging may be recommended to determine whether distant metastases are present. In women who are positive for distant metastases, biopsy of suspicious areas should be considered as indicated (see *Adjuvant Treatment* in the NCCN Guidelines for Cervical Cancer). For patients without distant metastases, recommended treatment is extended-field EBRT (including pelvic and para-aortic lymph nodes) with concurrent cisplatin-based chemotherapy and with (or without) brachytherapy. For patients with distant metastases, recommended treatment is systemic chemotherapy (see *Chemotherapy Regimens for Recurrent or Metastatic Cervical*

*Cancer* in the NCCN Guidelines) with (or without) individualized EBRT.<sup>187</sup>

Although neoadjuvant chemotherapy followed by surgery has been used in areas where RT is not available, data suggest no improvement in survival when compared with surgery alone for early-stage cervical cancer<sup>197-199</sup> or locally-advanced cervical cancer.<sup>200,201</sup> A meta-analysis of data on patients with stage IB1 to IIA cervical cancer found that neoadjuvant chemotherapy may reduce the need for adjuvant RT by decreasing tumor size and metastases, but indicated no overall survival benefit.<sup>201</sup> However, data from a second meta-analysis suggested that response to neoadjuvant chemotherapy was a strong prognostic factor for PFS and overall survival.<sup>202,203</sup> Outside of the clinical trial, the panel does not recommend the use of neoadjuvant chemotherapy.

## Surveillance

The panel agrees with the new Society of Gynecologic Oncology’s recommendations for post-treatment surveillance.<sup>204</sup> The recommended surveillance is based on the patient’s risk for recurrence and personal preferences. History and physical examination is recommended every 3 to 6 months for 2 years, every 6 to 12 months for another 3 to 5 years, and then annually (see *Surveillance* in the NCCN Guidelines for Cervical Cancer). Patients with high-risk disease can be assessed more frequently (eg, every 3 months for the first 2 years) than patients with low-risk disease (eg, every 6 months).

Annual cervical/vaginal cytology tests can be considered as indicated for detection of lower genital tract dysplasia (eg, for those who have had fertility-sparing surgery). Some clinicians have suggested that rigorous cytology follow-up is not warranted because of studies stating that Pap smears did not detect recurrences in patients with stage I or II cervical cancer who were asymptomatic after treatment.<sup>204-206</sup> Noting the



inherent differences between these patients and the general screening population, the panel does not recommend workup of low-grade squamous dysplasia detected during surveillance, but suggests that patients should follow up with a provider with specific expertise in this area. It is important to emphasize good clinical evaluation and a high index of suspicion, because the detection rate of recurrent cervical cancer is low using cervical and vaginal cytology alone.<sup>207</sup>

For patients with stage I disease, follow-up imaging should be based on symptomatology and clinical concern for recurrent/metastatic disease, such as abnormal physical exam finding or new pelvic, abdominal, or pulmonary symptoms. If fertility sparing treatment was provided, pelvic MRI should be considered 6 months after surgery and yearly for 2 to 3 years. PET/CT can be considered if metastasis is suspected. For patients with stage II disease or greater, PET/CT (preferred) or CT should be performed within 3 to 6 months of completing therapy, pelvic MRI is optional. Additional imaging should be guided by symptomatology and clinical concern for recurrent/metastatic disease. Specific indications and recommendations for surveillance imaging are detailed in *Principles of Imaging* in the NCCN Guidelines for Cervical Cancer.<sup>204,208-216</sup>

Many other tests remain optional based on clinical indications, such as semiannual CBCs, blood urea nitrogen, and serum creatinine determinations (see *Surveillance* in the NCCN Guidelines for Cervical Cancer). Patients with persistent or recurrent disease need to be evaluated using additional imaging studies as clinically indicated and surgical exploration in selected cases followed by therapy for relapse (see next section).<sup>217</sup>

Patient education regarding symptoms suggestive of recurrence is recommended (eg, vaginal discharge; weight loss; anorexia; pain in the

pelvis, hips, back, or legs; persistent coughing). Patients should also be counseled on healthy lifestyle, obesity, nutrition, exercise, sexual health, and potential long-term and late effects of treatment. Smoking cessation and abstinence should be encouraged.<sup>204</sup> See the NCCN Guidelines for Survivorship, the NCCN guidelines for Smoking Cessation, and <http://www.cancer.org/treatment/survivorship>).

Patients who have received RT for cervical cancer may experience vaginal stenosis and dryness and should receive education on important issues regarding sexual health and vaginal health. Providers should inform patients about regular vaginal intercourse and/or vaginal dilator use and on the use of vaginal moisturizers/lubricants (eg, estrogen creams). Anecdotal evidence suggests that vaginal dilators may be used to prevent or treat vaginal stenosis.<sup>218</sup> Dilator use can start 2 to 4 weeks after RT is completed and can be performed indefinitely ([http://www.mskcc.org/patient\\_education/assets/downloads-english/571.pdf](http://www.mskcc.org/patient_education/assets/downloads-english/571.pdf)).

Cervical cancer survivors are at risk for second cancers.<sup>219</sup> Data suggest that patients who undergo RT for pelvic cancers are at risk for radiation-induced second cancers, especially at radiated sites near the cervix (eg, colon, rectum/anus, urinary bladder); therefore, careful surveillance is appropriate for these patients.<sup>220,221</sup>

## Therapy for Relapse

Recurrences should be proven by biopsy before proceeding to treatment planning for recurrent disease.

## Locoregional Therapy

Patients with a localized recurrence of cervical cancer after initial treatment may be candidates for radical retreatment; options include: 1) RT and/or chemotherapy; or 2) surgery.<sup>129,222</sup> After treatment for relapse,

long-term, disease-free survival rates of approximately 40% have been reported in some situations.<sup>223</sup>

For patients who experience locoregional recurrences who have not undergone previous RT or who experience recurrences outside of the previously treated RT field, therapy for relapse includes tumor-directed EBRT with (or without) chemotherapy and/or brachytherapy; surgical resection can be considered if feasible (see *Therapy for Relapse* in the NCCN Guidelines for Cervical Cancer). Typically, the chemoradiation for recurrence uses cisplatin as a single agent or cisplatin plus 5-FU.<sup>224,225</sup> However, in those patients who have relapsed soon after completing initial chemoradiation with these regimens, alternative concurrent chemotherapy agents such as carboplatin, paclitaxel, and gemcitabine may be considered.

Patients with central pelvic recurrent disease after RT should be evaluated for pelvic exenteration, with (or without) intraoperative RT (IORT), although IORT is category 3.<sup>226-233</sup> Surgical mortality is generally 5% or less, with survival rates approaching 50% in carefully selected patients.<sup>229</sup> Concomitant measures with these radical procedures include adequate rehabilitation programs dealing with the psychosocial and psychosexual consequences of the surgery as well as reconstructive procedures.<sup>228,234-236</sup> Although exenteration is the common surgical approach in postradiation patients with isolated central pelvic relapse, radical hysterectomy or brachytherapy may be an option in carefully selected patients with small central lesions (<2 cm).

For patients with noncentral recurrent disease, options include EBRT with (or without) chemotherapy, resection with (or without) IORT (category 3 for IORT), chemotherapy, best supportive care (see the NCCN Guidelines for Palliative Care), or participation in a clinical trial. Patients who experience recurrence after second-line definitive therapy,

either surgery or RT, have a poor prognosis. They can be treated with chemotherapy or best supportive care, or can be enrolled in a clinical trial.

### Therapy for Metastatic Disease

Patients who develop distant metastases, either at initial presentation or at relapse, are rarely curable. For highly selected patients with isolated distant metastases amenable to local treatment, occasional long-term survival has been reported with: 1) surgical resection with (or without) EBRT; 2) Local ablative therapies with (or without) EBRT; or 3) EBRT with (or without) chemotherapy (see *Therapy for Relapse* in the NCCN Guidelines for Cervical Cancer). Systemic adjuvant chemotherapy can be considered. For example, patients who may benefit from aggressive local therapy for oligometastatic disease include those with nodal, lung, liver, or bone metastases. Following local therapy, additional adjuvant chemotherapy can be considered. For most other patients with distant metastases, an appropriate approach is a clinical trial, chemotherapy (see *Chemotherapy Regimens for Recurrent or Metastatic Cervical Cancer* in the NCCN Guidelines for Cervical Cancer), or best supportive care (see NCCN Guidelines for Palliative Care at [www.NCCN.org](http://www.NCCN.org)).

The palliation of pelvic recurrences in heavily irradiated sites that are not amenable to local pain control techniques or to surgical resection is difficult. These sites are generally not responsive to chemotherapy. Adequately palliating the complications of pain and fistulae from these recurrences is clinically challenging (<http://emedicine.medscape.com/article/270646-overview>). However, short courses of RT may provide symptomatic relief to patients with bone metastases, painful para-aortic nodes, or supraclavicular adenopathy.<sup>187,237,238</sup>

Chemotherapy is often recommended for patients with extrapelvic metastases or recurrent disease who are not candidates for RT or exenterative surgery. Patients whose disease responds to chemotherapy may have relief from pain and other symptoms. If cisplatin was previously used as a radiosensitizer, combination platinum-based regimens are preferred over single agents in the metastatic disease setting based on several randomized phase III trials (see next paragraph).<sup>239,240</sup> However, responses to chemotherapy are often of short duration and survival is rarely increased.

#### **First-Line Combination Chemotherapy**

Cisplatin has been considered the most effective agent for metastatic cervical cancer.<sup>241</sup> However, most patients who develop metastatic disease have received concurrent cisplatin/RT as primary treatment and may no longer be sensitive to single-agent platinum therapy.<sup>239,240</sup> Cisplatin-based combination chemotherapy regimens, such as cisplatin/paclitaxel/bevacizumab (category 1), cisplatin/paclitaxel (category 1), and cisplatin/topotecan (category 2A), have been extensively investigated in clinical studies.<sup>239,240,242-245</sup> A randomized phase III study (GOG 169) in 264 patients compared cisplatin/paclitaxel versus cisplatin alone for metastatic, recurrent, or persistent cervical cancer. Patients receiving the 2-drug combination had a higher response rate (36% vs. 19%) and improved PFS (4.8 months vs. 2.8 months;  $P > .001$ ) compared to single-agent cisplatin, although no improvement was seen in median survival.<sup>239</sup> Patients who responded to cisplatin/paclitaxel had a significant improvement in quality of life.

Another randomized phase III study (GOG 179) in 294 patients investigated cisplatin/topotecan versus cisplatin alone for recurrent or persistent cervical cancer. The topotecan combination regimen was shown to be superior to single-agent cisplatin with respect to overall response rate (27% vs. 13%,  $P = .004$ ), PFS (4.6 months vs. 2.9

months;  $P = .014$ ), and median survival (9.4 months vs. 6.5 months;  $P = .017$ ).<sup>240</sup> The FDA (Food and Drug Administration) has approved cisplatin/topotecan for advanced cervical cancer. However, the cisplatin/paclitaxel or carboplatin/paclitaxel regimens are less toxic and easier to administer than cisplatin/topotecan.<sup>246</sup>

A phase III trial (GOG 204) compared 4 cisplatin-doublet regimens (cisplatin/paclitaxel, cisplatin/topotecan, cisplatin/gemcitabine, and cisplatin/vinorelbine) in 513 patients with advanced metastatic or recurrent cancer.<sup>244</sup> The trial was closed early based on futility analysis, because it was apparent that the cisplatin/topotecan, cisplatin/gemcitabine (category 3), and cisplatin/vinorelbine regimens were not superior to the control arm of cisplatin/paclitaxel. No significant differences in overall survival were seen; however, the trends for response rate, PFS, and overall survival (12.9 months vs. 10 months) suggest that cisplatin/paclitaxel is superior to the other regimens. Cisplatin/paclitaxel was associated with less thrombocytopenia and anemia (but with more nausea, vomiting, infection, and alopecia) than the other regimens.

A recent randomized phase III trial (GOG 240) studied the addition of bevacizumab to combination chemotherapy regimens (cisplatin/paclitaxel/bevacizumab or topotecan/paclitaxel/bevacizumab) in 452 patients in the first-line setting of metastatic, persistent, or recurrent cervical cancer. An analysis of pooled data from the two chemotherapy regimens revealed significant improvements in overall survival among patients receiving bevacizumab (17.0 months vs. 13.3 months;  $P = .004$ ). While topotecan/paclitaxel (category 2A) was not shown to be superior to cisplatin/paclitaxel, it may be considered as an alternative in patients who are not candidates for cisplatin.<sup>245</sup> While bevacizumab led to higher toxicity (eg, hypertension, thromboembolic events, and gastrointestinal fistula), it was not associated with a

statistically significant decrease in patient-reported quality of life ( $P = .27$ ).<sup>247</sup> Based on these data, the FDA approved bevacizumab as part of combination therapy with paclitaxel and either cisplatin or topotecan for treating persistent, recurrent, or metastatic cervical cancer.<sup>248</sup> The panel has accepted both bevacizumab-containing regimens as category 1 options for treating persistent, recurrent, or metastatic cervical cancer.

Recently published data from a phase III randomized trial (JCOG0505) suggested that carboplatin/paclitaxel is non-inferior to cisplatin/paclitaxel in 253 women with metastatic or recurrent cervical cancer.<sup>249</sup> Many physicians use carboplatin/paclitaxel because of ease of administration and tolerability.<sup>250</sup> Results from JCOG0505 showed that the carboplatin/paclitaxel (TC) regimen was non-inferior to cisplatin/paclitaxel (TP) in terms of median overall survival (18.3 months for TP vs. 17.5 months for TC; HR=0.994 (90% CI, 0.79 to 1.25);  $P = .032$ ) and non-hospitalization periods were significantly longer for patients receiving TC.<sup>249</sup> However, among patients who had not received prior cisplatin, OS for TC and TP was 13.0 and 23.2 months, respectively (HR=1.571; 95% CI, 1.06 to 2.32).<sup>249</sup> Based on these data, the panel recommends carboplatin/paclitaxel as a category 1 option for patients who have received prior cisplatin therapy.

Carboplatin/paclitaxel is a category 2A recommendation for other indications (ie, for patients who have not received prior platinum-based therapy).

A recent systematic review of the data on cisplatin/paclitaxel and carboplatin/paclitaxel regimens also suggested that lower toxicity carboplatin-based regimens appear to be an equally effective alternative to cisplatin-based regimens for treating recurrent or metastatic cervical cancer.<sup>251</sup> Based on the collective findings from GOG 240 and JGOG0505, the panel has opted to include carboplatin/paclitaxel/bevacizumab as an additional treatment option for

recurrent or metastatic cervical cancer (category 2A). Based on the previous studies, cisplatin/paclitaxel and carboplatin/paclitaxel have become the most widely used systemic regimens for metastatic or recurrent cervical cancer. However, for patients who may not be candidates for taxanes, cisplatin/topotecan and cisplatin/gemcitabine remain reasonable alternative regimens.<sup>183,240</sup> Nonplatinum regimens are also being studied and may be considered in patients who cannot tolerate platinum-based chemotherapy.<sup>252</sup>

### Single Agents

Cisplatin is generally regarded as the most active agent and is recommended as a first-line single-agent chemotherapy option for recurrent or metastatic cervical cancer; reported response rates are approximately 20% to 30%, with an occasional complete response.<sup>239,241,253,254</sup> Overall survival with cisplatin is approximately 6 to 9 months. Both carboplatin and paclitaxel have each been reported to be tolerable and efficacious and are also possible first-line single-agent chemotherapy.<sup>255-258</sup> Therefore, palliation with single agents—cisplatin, carboplatin, or paclitaxel—is a reasonable approach in patients with recurrent disease not amenable to surgical or radiotherapeutic approaches.

Other agents (that are category 2B unless otherwise indicated) that have shown responses or prolongation of PFS and may be useful as second-line therapy include bevacizumab,<sup>259</sup> docetaxel,<sup>260</sup> 5-FU,<sup>261</sup> gemcitabine,<sup>262</sup> ifosfamide,<sup>263,264</sup> irinotecan,<sup>265</sup> mitomycin,<sup>266</sup> albumin-bound paclitaxel (ie, nab-paclitaxel),<sup>267</sup> topotecan,<sup>268,269</sup> pemetrexed,<sup>270</sup> and vinorelbine.<sup>271</sup>

### Drug Reactions

Virtually all drugs have the potential to cause adverse reactions, either during or after infusion.<sup>272</sup> In cervical cancer treatment, drugs that more



commonly cause adverse reactions include carboplatin, cisplatin, docetaxel, liposomal doxorubicin, and paclitaxel. Most of these drug reactions are mild infusion reactions (ie, skin reactions, cardiovascular reactions, respiratory or throat tightness), but more severe allergic reactions (ie, life-threatening anaphylaxis) can occur.<sup>273,274</sup> In addition, patients can have severe infusion reactions and mild allergic reactions. Infusion reactions are more common with paclitaxel.<sup>275</sup> Allergic reactions (ie, true drug allergies) are more common with platinum agents (eg, cisplatin).<sup>275,276</sup>

Management of drug reactions is discussed in the NCCN Guidelines for Ovarian Cancer.<sup>275</sup> Importantly, patients who experienced severe life-threatening reactions should not receive the implicated agent again unless evaluated by an allergist or specialist in drug desensitization. If a mild allergic reaction previously occurred and it is appropriate to re-administer the drug, a desensitization regimen is recommended even if the symptoms have resolved. Various desensitization regimens have been published and should be followed.<sup>276-278</sup> Patients must be desensitized with each infusion if they have had a previous reaction. Almost all patients can be desensitized.<sup>272</sup> To maximize safety, patients should be desensitized in the intensive care unit.<sup>272</sup>

### **Other Agents**

Vaccine therapies currently have no established role in the treatment of cervical cancer at the present time, except in the setting of a clinical trial.<sup>279-281</sup> Targeted therapy (using small molecules or monoclonal antibodies) is currently used in various clinical trials.<sup>259,282-287</sup>

### **Best Supportive Care**

Patients with refractory systemic cancer warrant a comprehensive coordinated approach involving hospice care, pain consultants, and

emotional and spiritual support, individualized to the situation (see the NCCN Guidelines for Palliative Care).

### **Incidental Cervical Cancer**

Invasive cervical carcinoma is sometimes found incidentally after extrafascial hysterectomy. Workup for these patients includes history and physical examination, CBC (including platelets), and liver and renal function tests. Recommended radiologic imaging includes chest radiography, CT, or combined PET/CT; MRI may be performed if indicated to rule out gross residual disease. However, imaging is optional for patients with stage IB1 or smaller tumors (see *Incidental Finding of Invasive Cervical Cancer at Simple Hysterectomy* in the NCCN Guidelines for Cervical Cancer).

No definitive data are available to guide the appropriate adjuvant treatment of these patients. Surveillance is recommended for patients with stage IA1 cervical cancer who do not have LVSI. For patients with either stage IA1 with LVSI or with stage IA2 or higher tumors (pathologic findings), the panel believes that a reasonable treatment schema should be based on the status of the surgical margins. If margins are positive and imaging is negative for nodal disease, then pelvic RT with concurrent cisplatin-containing chemotherapy with (or without) individualized brachytherapy is recommended (see *Primary Treatment* in the NCCN Guidelines for Cervical Cancer).

If margins or imaging is negative in stage IA2 or greater tumors, options include: 1) pelvic RT with (or without) concurrent cisplatin-containing chemotherapy and brachytherapy; or 2) a complete parametrectomy, upper vaginectomy, and pelvic lymph node dissection with (or without) para-aortic lymph node sampling. Typically, observation is recommended for patients with negative lymph nodes. However, pelvic radiation with (or without) vaginal brachytherapy is an option if they

have high-risk factors (ie, large primary tumor, deep stromal invasion, LVSI) (see *Primary Treatment* in the NCCN Guidelines for Cervical Cancer).<sup>192</sup> Concurrent cisplatin-based chemoradiation is recommended for gross residual disease, positive imaging, disease in the lymph nodes and/or parametrium, and/or a positive surgical margin; individualized brachytherapy is clearly indicated for a positive vaginal margin.

## Radiation Therapy

RT is often used in the management of patients with cervical cancer either 1) as definitive therapy for those with locally advanced disease or for those who are poor surgical candidates; or 2) as adjuvant therapy following radical hysterectomy for those who have one or more pathologic risk factors (eg, positive lymph nodes, parametrial infiltration, positive surgical margins, large tumor size, deep stromal invasion, LVSI).

The algorithm provides general RT dosage recommendations, which are expanded in the *Principles of Radiation Therapy* (see the NCCN Guidelines for Cervical Cancer). These RT dosages should not be interpreted as stand-alone recommendations, because RT techniques and clinical judgment are an essential part of developing an appropriate treatment regimen.

Optimum staging of disease to precisely delineate the primary tumor volume and draining lymph nodes, including abdominopelvic radiologic studies (CT, MRI, or combined PET/CT scans), is recommended in patients with stage IB2, IIA2, or advanced-stage tumors. Contemporary imaging studies must be correlated with careful assessment of clinical findings to define tumor extent, especially with regard to vaginal or parametrial extension.

## Radiation Treatment Planning

Technologic advances in imaging, computer treatment planning systems, and linear accelerator technology have enabled the more precise delivery radiation doses to the pelvis. However, physical accuracy of dose delivery must be matched to a clear understanding of tumor extent, potential pathways of spread, and historical patterns of locoregional recurrence to avoid geographic misses.

CT-based treatment planning with conformal blocking and dosimetry is considered standard care for external-beam RT. Brachytherapy is a critical component of definitive therapy in patients with cervical cancer who are not candidates for surgery (ie, those with an intact cervix); it may also be used as adjuvant therapy. Brachytherapy is typically combined with external-beam radiation in an integrated treatment plan. MRI imaging immediately preceding brachytherapy may be helpful in delineating residual tumor geometry. Stereotactic body radiotherapy (SBRT) allows delivery of very high doses of focused external beam radiation and may be applied to isolated metastatic sites.<sup>288,289</sup>

Routine image guidance, such as cone-beam CT (CBCT), may be helpful in defining daily internal soft tissue positioning. Concepts regarding the gross target volume (GTV), clinical target volume (CTV), planning target volume (PTV), organs at risk (OARs) and dose-volume histogram (DVH) have been defined for use in conformal radiotherapy, especially for IMRT.<sup>290-292</sup>

Point A, representing a paracervical reference point, has been the most widely used, validated, and reproducible dosing parameter used to date. However, limitations of the Point A dosing system include the fact that it does not take into account the three-dimension shape of tumors, nor individual tumor to normal tissue structure correlations. There are increasing efforts to use and standardize image-based volumetric

brachytherapy approaches using MR, CT or ultrasound - international validation efforts are underway (EMBRACE, NCT00920920).<sup>293-295</sup>

For patients with locally advanced cancers, initial radiation treatment of 40 to 45 Gy to the whole pelvis is often necessary to obtain tumor shrinkage to permit optimal intracavitary placements. With low-dose-rate intracavitary systems, total doses from brachytherapy and external-beam radiation to point A of at least 80 Gy are currently recommended for small tumors, with doses of 85 Gy or higher recommended for larger tumors

([http://www.americanbrachytherapy.org/guidelines/cervical\\_cancer\\_task\\_group.pdf](http://www.americanbrachytherapy.org/guidelines/cervical_cancer_task_group.pdf)).<sup>129</sup>

For lesions in the lower one third of the vagina, the inguinal lymph nodes must be treated. The use of extended-field radiation to treat occult or macroscopic para-aortic lymph node disease must be carefully planned to ensure an adequate dose (45 Gy for microscopic disease) without exceeding bowel, spinal cord, or renal tolerances.<sup>296</sup> General recommendations for radiation volumes and doses are discussed in the algorithm (see *Principles of Radiation Therapy for Cervical Cancer* in the NCCN Guidelines for Cervical Cancer).

Intensity-modulated RT (IMRT) is becoming more widely available; however, issues regarding target definition, patient and target immobilization, tissue deformation, toxicity and reproducibility remain to be validated.<sup>297-304</sup> Initial phase II hematologic toxicity data from RTOG 418 suggested that limiting the volume of bone marrow treated with IMRT was an important consideration for patients with cervical cancer who were receiving concurrent chemotherapy.<sup>305</sup> The ongoing TIME-C trial (RTOG 1203, NCT01672892) is comparing post-hysterectomy patients receiving adjuvant IMRT or standard (3D) RT to determine whether IMRT reduces acute gastrointestinal toxicity.<sup>306</sup>

Several retrospective analyses suggest that prolonged RT treatment duration has an adverse effect on outcome.<sup>307-311</sup> Extending the overall treatment beyond 6 to 8 weeks can result in approximately a 0.5% to 1% decrease in pelvic control and cause specific survival for each extra day of overall treatment time. Thus, although no prospective randomized trials have been performed, it is generally accepted that the entire RT course (including both external-beam RT and brachytherapy components) should be completed in a timely fashion (within 8 weeks); delays or splits in the radiation treatment should be avoided whenever possible.

### Normal Tissue Considerations

Planning for RT in cervical cancer must take into account the potential impact on surrounding critical structures, such as rectum, bladder, sigmoid, small bowel, and bone. Acute effects (ie, diarrhea, bladder irritation, fatigue) occur to some degree in most patients undergoing radiation and are typically magnified by concurrent chemotherapy. However, acute effects can often be managed with medications and supportive care, and they generally resolve soon after completion of radiation. To avoid treatment-related menopause, ovarian transposition can be considered before pelvic RT in select young patients (<45 years with early-stage disease).<sup>134-136</sup>

After therapy for cervical cancer, late side effects may include potential injury to bladder, rectum, bowel, and pelvic skeletal structures.<sup>312</sup> The risk of major complications (eg, obstruction, fibrosis/necrosis, and fistula) is related to the volume, total dose, dose per fraction, and specific intrinsic radiosensitivity of the normal tissue that is irradiated.<sup>296,313,314</sup> Careful blocking in order to minimize normal tissue exposure while maintaining tumor coverage is critical for optimal outcomes. In addition, patient-related conditions (ie, inflammatory bowel

disease, collagen-vascular disease, multiple abdominal/pelvic surgeries, history of pelvic inflammatory disease, diabetes) influence determination of radiation dose and volumes.

For most patients, it is generally accepted that the whole pelvis can tolerate an external-beam radiation dose of 40 to 50 Gy. Gross disease in the parametria or unresected nodes may be treated with tightly contoured external-beam boosts to 60 to 65 Gy. Intracavitary brachytherapy boosts require attention to proper placement of the applicators within the uterus and against the cervix and vaginal apex, as well as appropriate packing to maximally displace the bladder and rectum. SBRT is not considered an appropriate routine alternative to brachytherapy.

### Cervical Cancer and Pregnancy

Cervical cancer is the most frequently diagnosed gynecologic malignancy in pregnant women; however, most women have stage I disease.<sup>315-318</sup> Invasive cervical cancer during pregnancy creates a clinical dilemma and requires multidisciplinary care.<sup>315,319</sup> Women must make the difficult decision either to delay treatment until documented fetal maturity or to undergo immediate treatment based on their stage of disease.<sup>316,319</sup> Women who delay treatment until fetal maturity should have their children delivered by cesarean section.<sup>318,320,321</sup> Radical trachelectomy with preservation of pregnancy has been successfully performed in a few pregnant patients with early-stage cervical cancer.<sup>63,322-324</sup>

Patients with early-stage disease may prefer to have radical hysterectomy and node dissection instead of RT to avoid radiation fibrosis and to preserve their ovaries. Patients with Stage I disease who delay treatment until fetal maturity can undergo cesarean section with concurrent radical hysterectomy and pelvic node dissection. For those

choosing RT, traditional RT with (or without) chemotherapy protocols (described previously) may need to be modified.<sup>318</sup>

### Summary

Cervical cancer is decreasing in the United States because of the wide use of screening; however, it is increasing in developing countries (~275,000 deaths/year), because screening is not available to many women. Effective treatment for cervical cancer (including surgery and concurrent chemoradiation) can yield cures in 80% of women with early-stage disease (stages I–II) and in 60% of women with stage III disease. The hope is that immunization against HPV (using vaccines) will prevent persistent infection with the types of HPV against which the vaccine is designed, and will therefore prevent specific HPV cancer in women.<sup>15,16,325</sup>



**Table 1:**  
**Estimates of the Relative Risk of Death in Five Clinical Trials of Concurrent Chemotherapy and Radiotherapy**

Study*	FIGO Stage	Control Group	Comparison Group	Relative Risk of Death in Comparison Group
Keys et al.†	IB2	Radiotherapy	Radiotherapy plus weekly cisplatin	0.54
Rose, Bundy, Watkins et al.†	IIB-IVA	Radiotherapy plus hydroxyurea	Radiotherapy plus weekly cisplatin	0.61
			Radiotherapy plus cisplatin, fluorouracil, and hydroxyurea	0.58
Morris et al.†	IB2-IVA	Extended-field radiotherapy	Radiotherapy plus cisplatin and fluorouracil	0.52
Whitney et al.	IIB-IVA	Radiotherapy plus hydroxyurea	Radiotherapy plus cisplatin and fluorouracil	0.72
Peters et al.	IB or IIA (selected postoperatively)	Radiotherapy	Radiotherapy plus cisplatin and fluorouracil	0.50

Abbreviation: FIGO, International Federation of Gynecology and Obstetrics.

\*See Discussion for all references.

†These studies have been updated (see Discussion).

Used with permission from Thomas GM. Improved treatment for cervical cancer concurrent chemotherapy and radiotherapy. N Engl J Med 1999;340(15):1198-1200. Copyright© 1999 Massachusetts Medical Society. All rights reserved.

## References

1. Siegel RL, Miller KD, Jemal A. Cancer statistics, 2016. *CA Cancer J Clin* 2016;66:7-30. Available at: <http://www.ncbi.nlm.nih.gov/pubmed/26742998>.
2. Barnholtz-Sloan J, Patel N, Rollison D, et al. Incidence trends of invasive cervical cancer in the United States by combined race and ethnicity. *Cancer Causes Control* 2009;20:1129-1138. Available at: <http://www.ncbi.nlm.nih.gov/pubmed/19253025>.
3. Wang SS, Carreon JD, Gomez SL, Devesa SS. Cervical cancer incidence among 6 asian ethnic groups in the United States, 1996 through 2004. *Cancer* 2010;116:949-956. Available at: <http://www.ncbi.nlm.nih.gov/pubmed/20029972>.
4. Howe HL, Wu X, Ries LAG, et al. Annual report to the nation on the status of cancer, 1975-2003, featuring cancer among U.S. Hispanic/Latino populations. *Cancer* 2006;107:1711-1742. Available at: <http://www.ncbi.nlm.nih.gov/pubmed/16958083>.
5. Sherman ME, Wang SS, Carreon J, Devesa SS. Mortality trends for cervical squamous and adenocarcinoma in the United States. Relation to incidence and survival. *Cancer* 2005;103:1258-1264. Available at: <http://www.ncbi.nlm.nih.gov/pubmed/15693030>.
6. Cervical Cancer: Estimated Incidence, Mortality and Prevalence Worldwide in 2012. International Agency for Research on Cancer and World Health Organization; 2012. Available at: [http://globocan.iarc.fr/Pages/fact\\_sheets\\_cancer.aspx](http://globocan.iarc.fr/Pages/fact_sheets_cancer.aspx). Accessed January 26, 2015.
7. Parkin DM, Bray F, Ferlay J, Pisani P. Global cancer statistics, 2002. *CA Cancer J Clin* 2005;55:74-7108. Available at: <http://www.ncbi.nlm.nih.gov/pubmed/15761078>.
8. Kamangar F, Dores GM, Anderson WF. Patterns of cancer incidence, mortality, and prevalence across five continents: defining priorities to reduce cancer disparities in different geographic regions of the world. *J Clin Oncol* 2006;24:2137-2150. Available at: <http://www.ncbi.nlm.nih.gov/pubmed/16682732>.
9. Jemal A, Bray F, Center MM, et al. Global cancer statistics. *CA Cancer J Clin* 2011;61:69-90. Available at: <http://www.ncbi.nlm.nih.gov/pubmed/21296855>.
10. Kjaer SK, Frederiksen K, Munk C, Iftner T. Long-term absolute risk of cervical intraepithelial neoplasia grade 3 or worse following human papillomavirus infection: role of persistence. *J Natl Cancer Inst* 2010;102:1478-1488. Available at: <http://www.ncbi.nlm.nih.gov/pubmed/20841605>.
11. Rodriguez AC, Schiffman M, Herrero R, et al. Longitudinal study of human papillomavirus persistence and cervical intraepithelial neoplasia grade 2/3: critical role of duration of infection. *J Natl Cancer Inst* 2010;102:315-324. Available at: <http://www.ncbi.nlm.nih.gov/pubmed/20157096>.
12. Villa LL, Costa RL, Petta CA, et al. Prophylactic quadrivalent human papillomavirus (types 6, 11, 16, and 18) L1 virus-like particle vaccine in young women: a randomised double-blind placebo-controlled multicentre phase II efficacy trial. *Lancet Oncol* 2005;6:271-278. Available at: <http://www.ncbi.nlm.nih.gov/pubmed/15863374>.
13. Ault KA. Effect of prophylactic human papillomavirus L1 virus-like-particle vaccine on risk of cervical intraepithelial neoplasia grade 2, grade 3, and adenocarcinoma in situ: a combined analysis of four randomised clinical trials. *Lancet* 2007;369:1861-1868. Available at: <http://www.ncbi.nlm.nih.gov/pubmed/17544766>.
14. Quadrivalent vaccine against human papillomavirus to prevent high-grade cervical lesions. *N Engl J Med* 2007;356:1915-1927. Available at: <http://www.ncbi.nlm.nih.gov/pubmed/17494925>.
15. Arbyn M, Dillner J. Review of current knowledge on HPV vaccination: an appendix to the European Guidelines for Quality

Assurance in Cervical Cancer Screening. *J Clin Virol* 2007;38:189-197. Available at: <http://www.ncbi.nlm.nih.gov/pubmed/17258503>.

16. Rambout L, Hopkins L, Hutton B, Fergusson D. Prophylactic vaccination against human papillomavirus infection and disease in women: a systematic review of randomized controlled trials. *CMAJ* 2007;177:469-479. Available at: <http://www.ncbi.nlm.nih.gov/pubmed/17671238>.

17. Comparison of risk factors for invasive squamous cell carcinoma and adenocarcinoma of the cervix: collaborative reanalysis of individual data on 8,097 women with squamous cell carcinoma and 1,374 women with adenocarcinoma from 12 epidemiological studies. *Int J Cancer* 2007;120:885-891. Available at: <http://www.ncbi.nlm.nih.gov/pubmed/17131323>.

18. Dugue PA, Rebolj M, Garred P, Lynge E. Immunosuppression and risk of cervical cancer. *Expert Rev Anticancer Ther* 2013;13:29-42. Available at: <http://www.ncbi.nlm.nih.gov/pubmed/23259425>.

19. Bray F, Loos AH, McCarron P, et al. Trends in cervical squamous cell carcinoma incidence in 13 European countries: changing risk and the effects of screening. *Cancer Epidemiol Biomarkers Prev* 2005;14:677-686. Available at: <http://www.ncbi.nlm.nih.gov/pubmed/15767349>.

20. Watson M, Saraiya M, Benard V, et al. Burden of cervical cancer in the United States, 1998-2003. *Cancer* 2008;113:2855-2864. Available at: <http://www.ncbi.nlm.nih.gov/pubmed/18980204>.

21. Bray F, Carstensen B, Moller H, et al. Incidence trends of adenocarcinoma of the cervix in 13 European countries. *Cancer Epidemiol Biomarkers Prev* 2005;14:2191-2199. Available at: <http://www.ncbi.nlm.nih.gov/pubmed/16172231>.

22. Wang SS, Sherman ME, Hildesheim A, et al. Cervical adenocarcinoma and squamous cell carcinoma incidence trends among white women and black women in the United States for 1976-2000.

*Cancer* 2004;100:1035-1044. Available at: <http://www.ncbi.nlm.nih.gov/pubmed/14983500>.

23. Castellsague X, Diaz M, de Sanjose S, et al. Worldwide human papillomavirus etiology of cervical adenocarcinoma and its cofactors: implications for screening and prevention. *J Natl Cancer Inst* 2006;98:303-315. Available at: <http://www.ncbi.nlm.nih.gov/pubmed/16507827>.

24. Sasieni P, Castanon A, Cuzick J. Screening and adenocarcinoma of the cervix. *Int J Cancer* 2009;125:525-529. Available at: <http://www.ncbi.nlm.nih.gov/pubmed/19449379>.

25. Dahlstrom LA, Ylitalo N, Sundstrom K, et al. Prospective study of human papillomavirus and risk of cervical adenocarcinoma. *Int J Cancer* 2010;127:1923-1930. Available at: <http://www.ncbi.nlm.nih.gov/pubmed/20473898>.

26. Amit A, Schink J, Reiss A, Lowenstein L. PET/CT in gynecologic cancer: present applications and future prospects--a clinician's perspective. *Obstet Gynecol Clin North Am* 2011;38:1-21, vii. Available at: <http://www.ncbi.nlm.nih.gov/pubmed/21419325>.

27. Patel S, Liyanage SH, Sahdev A, et al. Imaging of endometrial and cervical cancer. *Insights Imaging* 2010;1:309-328. Available at: <http://www.ncbi.nlm.nih.gov/pubmed/22347925>.

28. ACOG practice bulletin. Diagnosis and treatment of cervical carcinomas. Number 35, May 2002. American College of Obstetricians and Gynecologists. *Int J Gynaecol Obstet* 2002;78:79-91. Available at: <http://www.ncbi.nlm.nih.gov/pubmed/12197489>.

29. Gold MA, Tian C, Whitney CW, et al. Surgical versus radiographic determination of para-aortic lymph node metastases before chemoradiation for locally advanced cervical carcinoma: a Gynecologic Oncology Group Study. *Cancer* 2008;112:1954-1963. Available at: <http://www.ncbi.nlm.nih.gov/pubmed/18338811>.

30. Monk BJ, Tian C, Rose PG, Lanciano R. Which clinical/pathologic factors matter in the era of chemoradiation as treatment for locally advanced cervical carcinoma? Analysis of two Gynecologic Oncology Group (GOG) trials. *Gynecol Oncol* 2007;105:427-433. Available at: <http://www.ncbi.nlm.nih.gov/pubmed/17275889>.
31. Siegel CL, Andreotti RF, Cardenas HR, et al. ACR Appropriateness Criteria(R) pretreatment planning of invasive cancer of the cervix. *J Am Coll Radiol* 2012;9:395-402. Available at: <http://www.ncbi.nlm.nih.gov/pubmed/22632665>.
32. Pecorelli S, Zigliani L, Odicino F. Revised FIGO staging for carcinoma of the cervix. *Int J Gynaecol Obstet* 2009;105:107-108. Available at: <http://www.ncbi.nlm.nih.gov/pubmed/19342051>.
33. Moore DH. Surgical staging and cervical cancer: after 30 years, have we reached a conclusion? *Cancer* 2008;112:1874-1876. Available at: <http://www.ncbi.nlm.nih.gov/pubmed/18348308>.
34. Pecorelli S. Revised FIGO staging for carcinoma of the vulva, cervix, and endometrium. *Int J Gynaecol Obstet* 2009;105:103-104. Available at: <http://www.ncbi.nlm.nih.gov/pubmed/19367689>.
35. Cervix Uteri Cancer Staging. American Joint Committee on Cancer; Available at: <http://cancerstaging.org/references-tools/quickreferences/Documents/CervixMedium.pdf> Accessed July 3, 2014.
36. How is cervical cancer staged? American Cancer Society; 2014. Available at: <http://www.cancer.org/acs/groups/cid/documents/webcontent/003094-pdf.pdf> Accessed July 3, 2014.
37. Hricak H, Gatsonis C, Coakley FV, et al. Early invasive cervical cancer: CT and MR imaging in preoperative evaluation - ACRIN/GOG comparative study of diagnostic performance and interobserver variability. *Radiology* 2007;245:491-498. Available at: <http://www.ncbi.nlm.nih.gov/pubmed/17940305>.
38. Woo S, Kim HS, Chung HH, et al. Early stage cervical cancer: role of magnetic resonance imaging after conization in determining residual tumor. *Acta Radiol* 2016;57:1268-1276. Available at: <http://www.ncbi.nlm.nih.gov/pubmed/26671305>.
39. Mitchell DG, Snyder B, Coakley F, et al. Early invasive cervical cancer: tumor delineation by magnetic resonance imaging, computed tomography, and clinical examination, verified by pathologic results, in the ACRIN 6651/GOG 183 Intergroup Study. *J Clin Oncol* 2006;24:5687-5694. Available at: <http://www.ncbi.nlm.nih.gov/pubmed/17179104>.
40. Downey K, Jafar M, Attygalle AD, et al. Influencing surgical management in patients with carcinoma of the cervix using a T2- and ZOOM-diffusion-weighted endovaginal MRI technique. *Br J Cancer* 2013;109:615-622. Available at: <http://www.ncbi.nlm.nih.gov/pubmed/23868012>.
41. Lakhman Y, Akin O, Park KJ, et al. Stage IB1 cervical cancer: role of preoperative MR imaging in selection of patients for fertility-sparing radical trachelectomy. *Radiology* 2013;269:149-158. Available at: <http://www.ncbi.nlm.nih.gov/pubmed/23788721>.
42. Downey K, Shepherd JH, Attygalle AD, et al. Preoperative imaging in patients undergoing trachelectomy for cervical cancer: validation of a combined T2- and diffusion-weighted endovaginal MRI technique at 3.0 T. *Gynecol Oncol* 2014;133:326-332. Available at: <http://www.ncbi.nlm.nih.gov/pubmed/24582988>.
43. de Boer P, Adam JA, Buist MR, et al. Role of MRI in detecting involvement of the uterine internal os in uterine cervical cancer: systematic review of diagnostic test accuracy. *Eur J Radiol* 2013;82:e422-428. Available at: <http://www.ncbi.nlm.nih.gov/pubmed/23711423>.
44. Thomeer MG, Gerestein C, Spronk S, et al. Clinical examination versus magnetic resonance imaging in the pretreatment staging of cervical carcinoma: systematic review and meta-analysis. *Eur Radiol*



2013;23:2005-2018. Available at:

<http://www.ncbi.nlm.nih.gov/pubmed/23455762>.

45. Park JY, Kim EN, Kim DY, et al. Comparison of the validity of magnetic resonance imaging and positron emission tomography/computed tomography in the preoperative evaluation of patients with uterine corpus cancer. *Gynecol Oncol* 2008;108:486-492. Available at: <http://www.ncbi.nlm.nih.gov/pubmed/18201753>.

46. Lin SY, Tsai CS, Chang YC, et al. The Role of Pretreatment FDG-PET in Treating Cervical Cancer Patients With Enlarged Pelvic Lymph Node(s) Shown on MRI: A Phase 3 Randomized Trial With Long-Term Follow-Up. *Int J Radiat Oncol Biol Phys* 2015;92:577-585. Available at: <http://www.ncbi.nlm.nih.gov/pubmed/25936817>.

47. Boughanim M, Leboulleux S, Rey A, et al. Histologic results of para-aortic lymphadenectomy in patients treated for stage IB2/II cervical cancer with negative [18F]fluorodeoxyglucose positron emission tomography scans in the para-aortic area. *J Clin Oncol* 2008;26:2558-2561. Available at: <http://www.ncbi.nlm.nih.gov/pubmed/18487573>.

48. Zhao Q, Feng Y, Mao X, Qie M. Prognostic value of fluorine-18-fluorodeoxyglucose positron emission tomography or PET-computed tomography in cervical cancer: a meta-analysis. *Int J Gynecol Cancer* 2013;23:1184-1190. Available at: <http://www.ncbi.nlm.nih.gov/pubmed/23851677>.

49. Bentivegna E, Gouy S, Maulard A, et al. Oncological outcomes after fertility-sparing surgery for cervical cancer: a systematic review. *Lancet Oncol* 2016;17:e240-253. Available at: <https://www.ncbi.nlm.nih.gov/pubmed/27299280>.

50. Ueki M, Okamoto Y, Misaki O, et al. Conservative therapy for microinvasive carcinoma of the uterine cervix. *Gynecol Oncol* 1994;53:109-113. Available at: <http://www.ncbi.nlm.nih.gov/pubmed/8175008>.

51. Al-Kalbani M, McVeigh G, Nagar H, McCluggage WG. Do FIGO stage IA and small ( $\leq 2$  cm) IB1 cervical adenocarcinomas have a good prognosis and warrant less radical surgery? *Int J Gynecol Cancer* 2012;22:291-295. Available at: <http://www.ncbi.nlm.nih.gov/pubmed/22080884>.

52. Webb JC, Key CR, Qualls CR, Smith HO. Population-based study of microinvasive adenocarcinoma of the uterine cervix. *Obstet Gynecol* 2001;97:701-706. Available at: <http://www.ncbi.nlm.nih.gov/pubmed/11339919>.

53. Sevin BU, Nadji M, Averette HE, et al. Microinvasive carcinoma of the cervix. *Cancer* 1992;70:2121-2128. Available at: <http://www.ncbi.nlm.nih.gov/pubmed/1394041>.

54. Huang LW, Hwang JL. A comparison between loop electrosurgical excision procedure and cold knife conization for treatment of cervical dysplasia: residual disease in a subsequent hysterectomy specimen. *Gynecol Oncol* 1999;73:12-15. Available at: <http://www.ncbi.nlm.nih.gov/pubmed/10094873>.

55. Miroshnichenko GG, Parva M, Holtz DO, et al. Interpretability of excisional biopsies of the cervix: cone biopsy and loop excision. *J Low Genit Tract Dis* 2009;13:10-12. Available at: <http://www.ncbi.nlm.nih.gov/pubmed/19098600>.

56. Greenspan DL, Faubion M, Coonrod DV, et al. Compliance after loop electrosurgical excision procedure or cold knife cone biopsy. *Obstet Gynecol* 2007;110:675-680. Available at: <http://www.ncbi.nlm.nih.gov/pubmed/17766617>.

57. Fanning J, Padratz J. Cold knife conization vs. LEEP. Are they the same procedure? *J Reprod Med* 2002;47:33-35. Available at: <http://www.ncbi.nlm.nih.gov/pubmed/11838307>.

58. Simmons JR, Anderson L, Hernandez E, Heller PB. Evaluating cervical neoplasia. LEEP as an alternative to cold knife conization. *J*

Reprod Med 1998;43:1007-1013. Available at:  
<http://www.ncbi.nlm.nih.gov/pubmed/9883402>.

59. Kim MK, Kim MA, Kim JW, et al. Loop electrosurgical excision procedure findings for identification of patients with early-stage cervical cancer suitable for less radical surgery. *Int J Gynecol Cancer* 2012;22:1214-1219. Available at:  
<http://www.ncbi.nlm.nih.gov/pubmed/22801033>.

60. Bouchard-Fortier G, Reade CJ, Covens A. Non-radical surgery for small early-stage cervical cancer. Is it time? *Gynecol Oncol* 2014;132:624-627. Available at:  
<http://www.ncbi.nlm.nih.gov/pubmed/24480237>.

61. Kato T, Takashima A, Kasamatsu T, et al. Clinical tumor diameter and prognosis of patients with FIGO stage IB1 cervical cancer (JCOG0806-A). *Gynecol Oncol* 2015;137:34-39. Available at:  
<http://www.ncbi.nlm.nih.gov/pubmed/25662625>.

62. Diaz JP, Sonoda Y, Leitao MM, et al. Oncologic outcome of fertility-sparing radical trachelectomy versus radical hysterectomy for stage IB1 cervical carcinoma. *Gynecol Oncol* 2008;111:255-260. Available at:  
<http://www.ncbi.nlm.nih.gov/pubmed/18755500>.

63. Abu-Rustum NR, Tal MN, DeLair D, et al. Radical abdominal trachelectomy for stage IB1 cervical cancer at 15-week gestation. *Gynecol Oncol* 2010;116:151-152. Available at:  
<http://www.ncbi.nlm.nih.gov/pubmed/19878979>.

64. Ramirez PT, Pareja R, Rendon GJ, et al. Management of low-risk early-stage cervical cancer: should conization, simple trachelectomy, or simple hysterectomy replace radical surgery as the new standard of care? *Gynecol Oncol* 2014;132:254-259. Available at:  
<http://www.ncbi.nlm.nih.gov/pubmed/24041877>.

65. Dargent D, Martin X, Sacchetoni A, Mathevet P. Laparoscopic vaginal radical trachelectomy: a treatment to preserve the fertility of

cervical carcinoma patients. *Cancer* 2000;88:1877-1882. Available at:  
<http://www.ncbi.nlm.nih.gov/pubmed/10760765>.

66. Viswanathan AN, Deavers MT, Jhingran A, et al. Small cell neuroendocrine carcinoma of the cervix: outcome and patterns of recurrence. *Gynecol Oncol* 2004;93:27-33. Available at:  
<http://www.ncbi.nlm.nih.gov/pubmed/15047210>.

67. Young RH, Clement PB. Endocervical adenocarcinoma and its variants: their morphology and differential diagnosis. *Histopathology* 2002;41:185-207. Available at:  
<http://www.ncbi.nlm.nih.gov/pubmed/12207781>.

68. Cao DY, Yang JX, Wu XH, et al. Comparisons of vaginal and abdominal radical trachelectomy for early-stage cervical cancer: preliminary results of a multi-center research in China. *Br J Cancer* 2013;109:2778-2782. Available at:  
<http://www.ncbi.nlm.nih.gov/pubmed/24169350>.

69. Plante M, Gregoire J, Renaud MC, Roy M. The vaginal radical trachelectomy: an update of a series of 125 cases and 106 pregnancies. *Gynecol Oncol* 2011;121:290-297. Available at:  
<http://www.ncbi.nlm.nih.gov/pubmed/21255824>.

70. Abu-Rustum NR, Sonoda Y, Black D, et al. Fertility-sparing radical abdominal trachelectomy for cervical carcinoma: technique and review of the literature. *Gynecol Oncol* 2006;103:807-813. Available at:  
<http://www.ncbi.nlm.nih.gov/pubmed/16837027>.

71. Einstein MH, Park KJ, Sonoda Y, et al. Radical vaginal versus abdominal trachelectomy for stage IB1 cervical cancer: a comparison of surgical and pathologic outcomes. *Gynecol Oncol* 2009;112:73-77. Available at:  
<http://www.ncbi.nlm.nih.gov/pubmed/18973933>.

72. Wethington SL, Cibula D, Duska LR, et al. An international series on abdominal radical trachelectomy: 101 patients and 28 pregnancies. *Int J Gynecol Cancer* 2012;22:1251-1257. Available at:  
<http://www.ncbi.nlm.nih.gov/pubmed/22914213>.

73. Abu-Rustum NR, Sonoda Y. Fertility-sparing surgery in early-stage cervical cancer: indications and applications. *J Natl Compr Canc Netw* 2010;8:1435-1438. Available at: <http://www.ncbi.nlm.nih.gov/pubmed/21147906>.
74. Beiner ME, Covens A. Surgery insight: radical vaginal trachelectomy as a method of fertility preservation for cervical cancer. *Nat Clin Pract Oncol* 2007;4:353-361. Available at: <http://www.ncbi.nlm.nih.gov/pubmed/17534391>.
75. Pareja R, Rendon GJ, Sanz-Lomana CM, et al. Surgical, oncological, and obstetrical outcomes after abdominal radical trachelectomy - a systematic literature review. *Gynecol Oncol* 2013;131:77-82. Available at: <http://www.ncbi.nlm.nih.gov/pubmed/23769758>.
76. Lintner B, Saso S, Tarnai L, et al. Use of abdominal radical trachelectomy to treat cervical cancer greater than 2 cm in diameter. *Int J Gynecol Cancer* 2013;23:1065-1070. Available at: <http://www.ncbi.nlm.nih.gov/pubmed/23722476>.
77. Wethington SL, Sonoda Y, Park KJ, et al. Expanding the indications for radical trachelectomy: a report on 29 patients with stage IB1 tumors measuring 2 to 4 centimeters. *Int J Gynecol Cancer* 2013;23:1092-1098. Available at: <http://www.ncbi.nlm.nih.gov/pubmed/23714706>.
78. Lanowska M, Mangler M, Speiser D, et al. Radical vaginal trachelectomy after laparoscopic staging and neoadjuvant chemotherapy in women with early-stage cervical cancer over 2 cm: oncologic, fertility, and neonatal outcome in a series of 20 patients. *Int J Gynecol Cancer* 2014;24:586-593. Available at: <http://www.ncbi.nlm.nih.gov/pubmed/24469326>.
79. Shepherd JH, Spencer C, Herod J, Ind TEJ. Radical vaginal trachelectomy as a fertility-sparing procedure in women with early-stage cervical cancer-cumulative pregnancy rate in a series of 123 women. *BJOG* 2006;113:719-724. Available at: <http://www.ncbi.nlm.nih.gov/pubmed/16709216>.
80. Park JY, Kim DY, Suh DS, et al. Reproductive outcomes after laparoscopic radical trachelectomy for early-stage cervical cancer. *J Gynecol Oncol* 2014;25:9-13. Available at: <http://www.ncbi.nlm.nih.gov/pubmed/24459575>.
81. Gizzo S, Ancona E, Saccardi C, et al. Radical trachelectomy: the first step of fertility preservation in young women with cervical cancer (Review). *Oncol Rep* 2013;30:2545-2554. Available at: <http://www.ncbi.nlm.nih.gov/pubmed/24065029>.
82. Cibula D, Abu-Rustum NR, Benedetti-Panici P, et al. New classification system of radical hysterectomy: emphasis on a three-dimensional anatomic template for parametrial resection. *Gynecol Oncol* 2011;122:264-268. Available at: <http://www.ncbi.nlm.nih.gov/pubmed/21592548>.
83. Querleu D, Morrow CP. Classification of radical hysterectomy. *Lancet Oncol* 2008;9:297-303. Available at: <http://www.ncbi.nlm.nih.gov/pubmed/18308255>.
84. Piver MS, Rutledge F, Smith JP. Five classes of extended hysterectomy for women with cervical cancer. *Obstet Gynecol* 1974;44:265-272. Available at: <http://www.ncbi.nlm.nih.gov/pubmed/4417035>.
85. Chi DS, Abu-Rustum NR, Plante M, Roy M. Cancer of the cervix. In: Rock JA, Jones HW, eds, eds. *TeLinde's Operative Gynecology*, 10th ed. Philadelphia: Lippincott Williams and Wilkins; 2008:1227.
86. Whitney CW, Spirtos NM. *Gynecologic Oncology Group Surgical Procedures Manual*. Philadelphia: Gynecologic Oncology Group; 2009. Available at: <https://gogmember.gog.org/manuals/pdf/surgman.pdf>. Accessed April 18, 2014.
87. Sardain H, Lavoue V, Redpath M, et al. Curative pelvic exenteration for recurrent cervical carcinoma in the era of concurrent chemotherapy and radiation therapy. A systematic review. *Eur J Surg Oncol*

2015;41:975-985. Available at:

<http://www.ncbi.nlm.nih.gov/pubmed/25922209>.

88. Chiantera V, Rossi M, De Iaco P, et al. Morbidity after pelvic exenteration for gynecological malignancies: a retrospective multicentric study of 230 patients. *Int J Gynecol Cancer* 2014;24:156-164. Available at: <http://www.ncbi.nlm.nih.gov/pubmed/24362721>.

89. Cormier B, Diaz JP, Shih K, et al. Establishing a sentinel lymph node mapping algorithm for the treatment of early cervical cancer. *Gynecol Oncol* 2011;122:275-280. Available at: <http://www.ncbi.nlm.nih.gov/pubmed/21570713>.

90. Lecuru F, Mathevet P, Querleu D, et al. Bilateral negative sentinel nodes accurately predict absence of lymph node metastasis in early cervical cancer: results of the SENTICOL study. *J Clin Oncol* 2011;29:1686-1691. Available at: <http://www.ncbi.nlm.nih.gov/pubmed/21444878>.

91. Altgassen C, Hertel H, Brandstadt A, et al. Multicenter validation study of the sentinel lymph node concept in cervical cancer: AGO Study Group. *J Clin Oncol* 2008;26:2943-2951. Available at: <http://www.ncbi.nlm.nih.gov/pubmed/18565880>.

92. Bats AS, Buenerd A, Querleu D, et al. Diagnostic value of intraoperative examination of sentinel lymph node in early cervical cancer: a prospective, multicenter study. *Gynecol Oncol* 2011;123:230-235. Available at: <http://www.ncbi.nlm.nih.gov/pubmed/21893335>.

93. Bats AS, Mathevet P, Buenerd A, et al. The sentinel node technique detects unexpected drainage pathways and allows nodal ultrastaging in early cervical cancer: insights from the multicenter prospective SENTICOL study. *Ann Surg Oncol* 2013;20:413-422. Available at: <http://www.ncbi.nlm.nih.gov/pubmed/22911367>.

94. Cibula D, Abu-Rustum NR, Dusek L, et al. Bilateral ultrastaging of sentinel lymph node in cervical cancer: Lowering the false-negative rate and improving the detection of micrometastasis. *Gynecol Oncol*

2012;127:462-466. Available at:

<http://www.ncbi.nlm.nih.gov/pubmed/22943880>.

95. Cibula D, Abu-Rustum NR, Dusek L, et al. Prognostic significance of low volume sentinel lymph node disease in early-stage cervical cancer. *Gynecol Oncol* 2012;124:496-501. Available at: <http://www.ncbi.nlm.nih.gov/pubmed/22120175>.

96. Fader AN, Edwards RP, Cost M, et al. Sentinel lymph node biopsy in early-stage cervical cancer: utility of intraoperative versus postoperative assessment. *Gynecol Oncol* 2008;111:13-17. Available at: <http://www.ncbi.nlm.nih.gov/pubmed/18684499>.

97. Lecuru F, Bats A, Mathevet P, et al. Impact of sentinel lymph node biopsy on staging of early cervical cancer: Results of a prospective, multicenter study [abstract]. *J Clin Oncol* 2009;27(Suppl 18):Abstract CRA5506. Available at: <http://meeting.ascopubs.org/cgi/content/abstract/27/18S/CRA5506>.

98. Slama J, Dunder P, Dusek L, Cibula D. High false negative rate of frozen section examination of sentinel lymph nodes in patients with cervical cancer. *Gynecol Oncol* 2013;129:384-388. Available at: <http://www.ncbi.nlm.nih.gov/pubmed/23395889>.

99. van de Lande J, Torrenza B, Raijmakers PGHM, et al. Sentinel lymph node detection in early stage uterine cervix carcinoma: a systematic review. *Gynecol Oncol* 2007;106:604-613. Available at: <http://www.ncbi.nlm.nih.gov/pubmed/17628644>.

100. Andikyan V, Khoury-Collado F, Denesopolis J, et al. Cervical conization and sentinel lymph node mapping in the treatment of stage I cervical cancer: is less enough? *Int J Gynecol Cancer* 2014;24:113-117. Available at: <http://www.ncbi.nlm.nih.gov/pubmed/24335661>.

101. Wu Y, Li Z, Wu H, Yu J. Sentinel lymph node biopsy in cervical cancer: A meta-analysis. *Mol Clin Oncol* 2013;1:1025-1030. Available at: <http://www.ncbi.nlm.nih.gov/pubmed/24649288>.



102. Kadkhodayan S, Hasanzadeh M, Treglia G, et al. Sentinel node biopsy for lymph nodal staging of uterine cervix cancer: a systematic review and meta-analysis of the pertinent literature. *Eur J Surg Oncol* 2015;41:1-20. Available at:

<http://www.ncbi.nlm.nih.gov/pubmed/25454828>.

103. Ruscito I, Gasparri ML, Braicu EI, et al. Sentinel Node Mapping in Cervical and Endometrial Cancer: Indocyanine Green Versus Other Conventional Dyes-A Meta-Analysis. *Ann Surg Oncol* 2016;23:3749-3756. Available at: <https://www.ncbi.nlm.nih.gov/pubmed/27160526>.

104. Eiriksson LR, Covens A. Sentinel lymph node mapping in cervical cancer: the future? *BJOG* 2012;119:129-133. Available at:

<http://www.ncbi.nlm.nih.gov/pubmed/21917113>.

105. Bats AS, Frati A, Mathevet P, et al. Contribution of lymphoscintigraphy to intraoperative sentinel lymph node detection in early cervical cancer: Analysis of the prospective multicenter SENTICOL cohort. *Gynecol Oncol* 2015;137:264-269. Available at:

<http://www.ncbi.nlm.nih.gov/pubmed/25727652>.

106. Darlin L, Persson J, Bossmar T, et al. The sentinel node concept in early cervical cancer performs well in tumors smaller than 2 cm.

*Gynecol Oncol* 2010;117:266-269. Available at:

<http://www.ncbi.nlm.nih.gov/pubmed/20167355>.

107. Sakuragi N, Satoh C, Takeda N, et al. Incidence and distribution pattern of pelvic and paraaortic lymph node metastasis in patients with Stages IB, IIA, and IIB cervical carcinoma treated with radical hysterectomy. *Cancer* 1999;85:1547-1554. Available at:

<http://www.ncbi.nlm.nih.gov/pubmed/10193945>.

108. Huang H, Liu J, Li Y, et al. Metastasis to deep obturator and para-aortic lymph nodes in 649 patients with cervical carcinoma. *Eur J Surg Oncol* 2011;37:978-983. Available at:

<http://www.ncbi.nlm.nih.gov/pubmed/21907530>.

109. Gouy S, Morice P, Narducci F, et al. Prospective multicenter study evaluating the survival of patients with locally advanced cervical cancer undergoing laparoscopic para-aortic lymphadenectomy before chemoradiotherapy in the era of positron emission tomography imaging.

*J Clin Oncol* 2013;31:3026-3033. Available at:

<http://www.ncbi.nlm.nih.gov/pubmed/23857967>.

110. Frumovitz M, Querleu D, Gil-Moreno A, et al. Lymphadenectomy in locally advanced cervical cancer study (LiLACS): Phase III clinical trial comparing surgical with radiologic staging in patients with stages IB-IVA cervical cancer. *J Minim Invasive Gynecol* 2014;21:3-8. Available at:

<http://www.ncbi.nlm.nih.gov/pubmed/23911560>.

111. Weinberg L, Rao S, Escobar PF. Robotic surgery in gynecology: an updated systematic review. *Obstet Gynecol Int* 2011;2011:852061.

Available at: <http://www.ncbi.nlm.nih.gov/pubmed/22190948>.

112. Sinno AK, Fader AN. Robotic-assisted surgery in gynecologic oncology. *Fertil Steril* 2014;102:922-932. Available at:

<http://www.ncbi.nlm.nih.gov/pubmed/25274485>.

113. Lowe MP, Chamberlain DH, Kamelle SA, et al. A multi-institutional experience with robotic-assisted radical hysterectomy for early stage cervical cancer.

*Gynecol Oncol* 2009;113:191-194. Available at:

<http://www.ncbi.nlm.nih.gov/pubmed/19249082>.

114. Nezhat FR, Datta MS, Liu C, et al. Robotic radical hysterectomy versus total laparoscopic radical hysterectomy with pelvic lymphadenectomy for treatment of early cervical cancer.

*JSLS* 2008;12:227-237. Available at:

<http://www.ncbi.nlm.nih.gov/pubmed/18765043>.

115. Cantrell LA, Mendivil A, Gehrig PA, Boggess JF. Survival outcomes for women undergoing type III robotic radical hysterectomy for cervical cancer: a 3-year experience. *Gynecol Oncol* 2010;117:260-265. Available at:

<http://www.ncbi.nlm.nih.gov/pubmed/20153886>.

116. Wang YZ, Deng L, Xu HC, et al. Laparoscopy versus laparotomy for the management of early stage cervical cancer. *BMC Cancer* 2015;15:928. Available at: <http://www.ncbi.nlm.nih.gov/pubmed/26596955>.
117. Marnitz S, Kohler C, Roth C, et al. Is there a benefit of pretreatment laparoscopic transperitoneal surgical staging in patients with advanced cervical cancer? *Gynecol Oncol* 2005;99:536-544. Available at: <http://www.ncbi.nlm.nih.gov/pubmed/16126259>.
118. Ramirez PT, Slomovitz BM, Soliman PT, et al. Total laparoscopic radical hysterectomy and lymphadenectomy: the M. D. Anderson Cancer Center experience. *Gynecol Oncol* 2006;102:252-255. Available at: <http://www.ncbi.nlm.nih.gov/pubmed/16472844>.
119. Abu-Rustum NR, Gemignani ML, Moore K, et al. Total laparoscopic radical hysterectomy with pelvic lymphadenectomy using the argon-beam coagulator: pilot data and comparison to laparotomy. *Gynecol Oncol* 2003;91:402-409. Available at: <http://www.ncbi.nlm.nih.gov/pubmed/14599873>.
120. Chi DS. Laparoscopy in gynecologic malignancies. *Oncology (Williston Park)* 1999;13:773-782. Available at: <http://www.ncbi.nlm.nih.gov/pubmed/10378217>.
121. Chen Y, Xu H, Li Y, et al. The outcome of laparoscopic radical hysterectomy and lymphadenectomy for cervical cancer: a prospective analysis of 295 patients. *Ann Surg Oncol* 2008;15:2847-2855. Available at: <http://www.ncbi.nlm.nih.gov/pubmed/18649105>.
122. Puntambekar SP, Palep RJ, Puntambekar SS, et al. Laparoscopic total radical hysterectomy by the Pune technique: our experience of 248 cases. *J Minim Invasive Gynecol* 2007;14:682-689. Available at: <http://www.ncbi.nlm.nih.gov/pubmed/17980327>.
123. Nam JH, Park JY, Kim DY, et al. Laparoscopic versus open radical hysterectomy in early-stage cervical cancer: long-term survival outcomes in a matched cohort study. *Ann Oncol* 2012;23:903-911. Available at: <http://www.ncbi.nlm.nih.gov/pubmed/21841155>.
124. Shazly SA, Murad MH, Dowdy SC, et al. Robotic radical hysterectomy in early stage cervical cancer: A systematic review and meta-analysis. *Gynecol Oncol* 2015;138:457-471. Available at: <http://www.ncbi.nlm.nih.gov/pubmed/26056752>.
125. Nevis IF, Vali B, Higgins C, et al. Robot-assisted hysterectomy for endometrial and cervical cancers: a systematic review. *J Robot Surg* 2016. Available at: <https://www.ncbi.nlm.nih.gov/pubmed/27424111>.
126. Park DA, Yun JE, Kim SW, Lee SH. Surgical and clinical safety and effectiveness of robot-assisted laparoscopic hysterectomy compared to conventional laparoscopy and laparotomy for cervical cancer: A systematic review and meta-analysis. *Eur J Surg Oncol* 2016. Available at: <https://www.ncbi.nlm.nih.gov/pubmed/27546015>.
127. Sert BM, Boggess JF, Ahmad S, et al. Robot-assisted versus open radical hysterectomy: A multi-institutional experience for early-stage cervical cancer. *Eur J Surg Oncol* 2016;42:513-522. Available at: <http://www.ncbi.nlm.nih.gov/pubmed/26843445>.
128. Mendivil AA, Rettenmaier MA, Abaid LN, et al. Survival rate comparisons amongst cervical cancer patients treated with an open, robotic-assisted or laparoscopic radical hysterectomy: A five year experience. *Surg Oncol* 2016;25:66-71. Available at: <http://www.ncbi.nlm.nih.gov/pubmed/26409687>.
129. Gaffney DK, Erickson-Wittmann BA, Jhingran A, et al. ACR Appropriateness Criteria(R) on Advanced Cervical Cancer Expert Panel on Radiation Oncology-Gynecology. *Int J Radiat Oncol Biol Phys* 2011;81:609-614. Available at: <http://www.ncbi.nlm.nih.gov/pubmed/21215531>.
130. Monk BJ, Tewari KS, Koh W-J. Multimodality therapy for locally advanced cervical carcinoma: state of the art and future directions. *J*

Clin Oncol 2007;25:2952-2965. Available at:  
<http://www.ncbi.nlm.nih.gov/pubmed/17617527>.

131. Gien LT, Beauchemin MC, Thomas G. Adenocarcinoma: a unique cervical cancer. Gynecol Oncol 2010;116:140-146. Available at:  
<http://www.ncbi.nlm.nih.gov/pubmed/19880165>.

132. Baalbergen A, Veenstra Y, Stalpers LL, Ansink AC. Primary surgery versus primary radiation therapy with or without chemotherapy for early adenocarcinoma of the uterine cervix. Cochrane Database Syst Rev 2010:CD006248. Available at:  
<http://www.ncbi.nlm.nih.gov/pubmed/20091590>.

133. Park JY, Kim DY, Kim JH, et al. Outcomes after radical hysterectomy in patients with early-stage adenocarcinoma of uterine cervix. Br J Cancer 2010;102:1692-1698. Available at:  
<http://www.ncbi.nlm.nih.gov/pubmed/20531414>.

134. Wo JY, Viswanathan AN. Impact of radiotherapy on fertility, pregnancy, and neonatal outcomes in female cancer patients. Int J Radiat Oncol Biol Phys 2009;73:1304-1312. Available at:  
<http://www.ncbi.nlm.nih.gov/pubmed/19306747>.

135. Pahisa J, Martinez-Roman S, Martinez-Zamora MA, et al. Laparoscopic ovarian transposition in patients with early cervical cancer. Int J Gynecol Cancer 2008;18:584-589. Available at:  
<http://www.ncbi.nlm.nih.gov/pubmed/18476952>.

136. Morice P, Juncker L, Rey A, et al. Ovarian transposition for patients with cervical carcinoma treated by radiosurgical combination. Fertil Steril 2000;74:743-748. Available at:  
<http://www.ncbi.nlm.nih.gov/pubmed/11020517>.

137. Landoni F, Maneo A, Colombo A, et al. Randomised study of radical surgery versus radiotherapy for stage Ib-IIa cervical cancer. Lancet 1997;350:535-540. Available at:  
<http://www.ncbi.nlm.nih.gov/pubmed/9284774>.

138. Keys HM, Bundy BN, Stehman FB, et al. Cisplatin, radiation, and adjuvant hysterectomy compared with radiation and adjuvant hysterectomy for bulky stage IB cervical carcinoma. N Engl J Med 1999;340:1154-1161. Available at:  
<http://www.ncbi.nlm.nih.gov/pubmed/10202166>.

139. Morris M, Eifel PJ, Lu J, et al. Pelvic radiation with concurrent chemotherapy compared with pelvic and para-aortic radiation for high-risk cervical cancer. N Engl J Med 1999;340:1137-1143. Available at:  
<http://www.ncbi.nlm.nih.gov/pubmed/10202164>.

140. Peters WA, Liu PY, Barrett RJ, et al. Concurrent chemotherapy and pelvic radiation therapy compared with pelvic radiation therapy alone as adjuvant therapy after radical surgery in high-risk early-stage cancer of the cervix. J Clin Oncol 2000;18:1606-1613. Available at:  
<http://www.ncbi.nlm.nih.gov/pubmed/10764420>.

141. Whitney CW, Sause W, Bundy BN, et al. Randomized comparison of fluorouracil plus cisplatin versus hydroxyurea as an adjunct to radiation therapy in stage IIB-IVA carcinoma of the cervix with negative para-aortic lymph nodes: a Gynecologic Oncology Group and Southwest Oncology Group study. J Clin Oncol 1999;17:1339-1348. Available at:  
<http://www.ncbi.nlm.nih.gov/pubmed/10334517>.

142. Rose PG, Bundy BN, Watkins EB, et al. Concurrent cisplatin-based radiotherapy and chemotherapy for locally advanced cervical cancer. N Engl J Med 1999;340:1144-1153. Available at:  
<http://www.ncbi.nlm.nih.gov/pubmed/10202165>.

143. Thomas GM. Improved treatment for cervical cancer--concurrent chemotherapy and radiotherapy. N Engl J Med 1999;340:1198-1200. Available at:  
<http://www.ncbi.nlm.nih.gov/pubmed/10202172>.

144. Rose PG, Ali S, Watkins E, et al. Long-term follow-up of a randomized trial comparing concurrent single agent cisplatin, cisplatin-based combination chemotherapy, or hydroxyurea during pelvic irradiation for locally advanced cervical cancer: a Gynecologic Oncology

Group Study. J Clin Oncol 2007;25:2804-2810. Available at: <http://www.ncbi.nlm.nih.gov/pubmed/17502627>.

145. Eifel PJ, Winter K, Morris M, et al. Pelvic irradiation with concurrent chemotherapy versus pelvic and para-aortic irradiation for high-risk cervical cancer: an update of radiation therapy oncology group trial (RTOG) 90-01. J Clin Oncol 2004;22:872-880. Available at: <http://www.ncbi.nlm.nih.gov/pubmed/14990643>.

146. Stehman FB, Ali S, Keys HM, et al. Radiation therapy with or without weekly cisplatin for bulky stage 1B cervical carcinoma: follow-up of a Gynecologic Oncology Group trial. Am J Obstet Gynecol 2007;197:1-6. Available at: <http://www.ncbi.nlm.nih.gov/pubmed/17980189>.

147. Reducing uncertainties about the effects of chemoradiotherapy for cervical cancer: a systematic review and meta-analysis of individual patient data from 18 randomized trials. J Clin Oncol 2008;26:5802-5812. Available at: <http://www.ncbi.nlm.nih.gov/pubmed/19001332>.

148. Pearcey R, Miao Q, Kong W, et al. Impact of adoption of chemoradiotherapy on the outcome of cervical cancer in Ontario: results of a population-based cohort study. J Clin Oncol 2007;25:2383-2388. Available at: <http://www.ncbi.nlm.nih.gov/pubmed/17557951>.

149. King M, McConkey C, Latief TN, et al. Improved survival after concurrent weekly cisplatin and radiotherapy for cervical carcinoma with assessment of acute and late side-effects. Clin Oncol (R Coll Radiol) 2006;18:38-45. Available at: <http://www.ncbi.nlm.nih.gov/pubmed/16477918>.

150. Tan LT, Zahra M. Long-term survival and late toxicity after chemoradiotherapy for cervical cancer--the Addenbrooke's experience. Clin Oncol (R Coll Radiol) 2008;20:358-364. Available at: <http://www.ncbi.nlm.nih.gov/pubmed/18395427>.

151. Gaffney DK, Du Bois A, Narayan K, et al. Practice patterns of radiotherapy in cervical cancer among member groups of the

Gynecologic Cancer Intergroup (GCIG). Int J Radiat Oncol Biol Phys 2007;68:485-490. Available at: <http://www.ncbi.nlm.nih.gov/pubmed/17336465>.

152. Cetina L, Garcia-Arias A, Uribe MdJ, et al. Concurrent chemoradiation with carboplatin for elderly, diabetic and hypertensive patients with locally advanced cervical cancer. Eur J Gynaecol Oncol 2008;29:608-612. Available at: <http://www.ncbi.nlm.nih.gov/pubmed/19115688>.

153. Dubay RA, Rose PG, O'Malley DM, et al. Evaluation of concurrent and adjuvant carboplatin with radiation therapy for locally advanced cervical cancer. Gynecol Oncol 2004;94:121-124. Available at: <http://www.ncbi.nlm.nih.gov/pubmed/15262129>.

154. Higgins RV, Naumann WR, Hall JB, Haake M. Concurrent carboplatin with pelvic radiation therapy in the primary treatment of cervix cancer. Gynecol Oncol 2003;89:499-503. Available at: <http://www.ncbi.nlm.nih.gov/pubmed/12798718>.

155. Lorvidhaya V, Chitapanarux I, Sangruchi S, et al. Concurrent mitomycin C, 5-fluorouracil, and radiotherapy in the treatment of locally advanced carcinoma of the cervix: a randomized trial. Int J Radiat Oncol Biol Phys 2003;55:1226-1232. Available at: <http://www.ncbi.nlm.nih.gov/pubmed/12654431>.

156. Wong LC, Ngan HY, Cheung AN, et al. Chemoradiation and adjuvant chemotherapy in cervical cancer. J Clin Oncol 1999;17:2055-2060. Available at: <http://www.ncbi.nlm.nih.gov/pubmed/10561258>.

157. Mileschkin LR, Narayan K, Moore KN, et al. A phase III trial of adjuvant chemotherapy following chemoradiation as primary treatment for locally advanced cervical cancer compared to chemoradiation alone: Outback (ANZGOG0902/GOG0274/RTOG1174) [abstract]. Journal of Clinical Oncology 2014 32:abstract TPS5632. Available at: [http://abstracts.asco.org/144/AbstView\\_144\\_132544.html](http://abstracts.asco.org/144/AbstView_144_132544.html).



158. Koliopoulos G, Sotiriadis A, Kyrgiou M, et al. Conservative surgical methods for FIGO stage IA2 squamous cervical carcinoma and their role in preserving women's fertility. *Gynecol Oncol* 2004;93:469-473. Available at: <http://www.ncbi.nlm.nih.gov/pubmed/15099964>.
159. Wright JD, NathavithArana R, Lewin SN, et al. Fertility-conserving surgery for young women with stage IA1 cervical cancer: safety and access. *Obstet Gynecol* 2010;115:585-590. Available at: <http://www.ncbi.nlm.nih.gov/pubmed/20177290>.
160. Diaz ES, Aoyama C, Baquing MA, et al. Predictors of residual carcinoma or carcinoma-in-situ at hysterectomy following cervical conization with positive margins. *Gynecol Oncol* 2014;132:76-80. Available at: <http://www.ncbi.nlm.nih.gov/pubmed/24262876>.
161. Tierney KE, Lin PS, Amezcua C, et al. Cervical conization of adenocarcinoma in situ: a predicting model of residual disease. *Am J Obstet Gynecol* 2014;210:366 e361-365. Available at: <http://www.ncbi.nlm.nih.gov/pubmed/24370689>.
162. Yoneda JY, Braganca JF, Sarian LO, et al. Surgical treatment of microinvasive cervical cancer: analysis of pathologic features with implications on radicality. *Int J Gynecol Cancer* 2015;25:694-698. Available at: <http://www.ncbi.nlm.nih.gov/pubmed/25742569>.
163. Bernardini M, Barrett J, Seaward G, Covens A. Pregnancy outcomes in patients after radical trachelectomy. *Am J Obstet Gynecol* 2003;189:1378-1382. Available at: <http://www.ncbi.nlm.nih.gov/pubmed/14634572>.
164. Boss EA, van Golde RJT, Beerendonk CCM, Massuger LFAG. Pregnancy after radical trachelectomy: a real option? *Gynecol Oncol* 2005;99:152-156. Available at: <http://www.ncbi.nlm.nih.gov/pubmed/16140367>.
165. Plante M, Renaud M-C, Hoskins IA, Roy M. Vaginal radical trachelectomy: a valuable fertility-preserving option in the management of early-stage cervical cancer. A series of 50 pregnancies and review of the literature. *Gynecol Oncol* 2005;98:3-10. Available at: <http://www.ncbi.nlm.nih.gov/pubmed/15936061>.
166. Marchiole P, Benchaib M, Buenerd A, et al. Oncological safety of laparoscopic-assisted vaginal radical trachelectomy (LARVT or Dargent's operation): a comparative study with laparoscopic-assisted vaginal radical hysterectomy (LARVH). *Gynecol Oncol* 2007;106:132-141. Available at: <http://www.ncbi.nlm.nih.gov/pubmed/17493666>.
167. Landoni F, Zanagnolo V, Lovato-Diaz L, et al. Ovarian metastases in early-stage cervical cancer (IA2-IIA): a multicenter retrospective study of 1965 patients (a Cooperative Task Force study). *Int J Gynecol Cancer* 2007;17:623-628. Available at: <http://www.ncbi.nlm.nih.gov/pubmed/17309669>.
168. Shimada M, Kigawa J, Nishimura R, et al. Ovarian metastasis in carcinoma of the uterine cervix. *Gynecol Oncol* 2006;101:234-237. Available at: <http://www.ncbi.nlm.nih.gov/pubmed/16300819>.
169. Kokka F, Bryant A, Brockbank E, Jeyarajah A. Surgical treatment of stage IA2 cervical cancer. *Cochrane Database Syst Rev* 2014:CD010870. Available at: <http://www.ncbi.nlm.nih.gov/pubmed/24874726>.
170. Small W, Jr., Strauss JB, Jhingran A, et al. ACR Appropriateness Criteria(R) definitive therapy for early-stage cervical cancer. *Am J Clin Oncol* 2012;35:399-405. Available at: <http://www.ncbi.nlm.nih.gov/pubmed/22810416>.
171. Raju SK, Papadopoulos AJ, Montalto SA, et al. Fertility-sparing surgery for early cervical cancer—approach to less radical surgery. *Int J Gynecol Cancer* 2012;22:311-317. Available at: <http://www.ncbi.nlm.nih.gov/pubmed/22237381>.
172. Li J, Wu X, Li X, Ju X. Abdominal radical trachelectomy: Is it safe for IB1 cervical cancer with tumors  $\geq$  2 cm? *Gynecol Oncol* 2013;131:87-92. Available at: <http://www.ncbi.nlm.nih.gov/pubmed/23872192>.

173. Landoni F, Maneo A, Cormio G, et al. Class II versus class III radical hysterectomy in stage IB-IIA cervical cancer: a prospective randomized study. *Gynecol Oncol* 2001;80:3-12. Available at: <http://www.ncbi.nlm.nih.gov/pubmed/11136561>.

174. Keys HM, Bundy BN, Stehman FB, et al. Radiation therapy with and without extrafascial hysterectomy for bulky stage IB cervical carcinoma: a randomized trial of the Gynecologic Oncology Group. *Gynecol Oncol* 2003;89:343-353. Available at: <http://www.ncbi.nlm.nih.gov/pubmed/12798694>.

175. Kokka F, Bryant A, Brockbank E, et al. Hysterectomy with radiotherapy or chemotherapy or both for women with locally advanced cervical cancer. *Cochrane Database Syst Rev* 2015;4:CD010260. Available at: <http://www.ncbi.nlm.nih.gov/pubmed/25847525>.

176. Colombo PE, Bertrand MM, Gutowski M, et al. Total laparoscopic radical hysterectomy for locally advanced cervical carcinoma (stages IIB, IIA and bulky stages IB) after concurrent chemoradiation therapy: surgical morbidity and oncological results. *Gynecol Oncol* 2009;114:404-409. Available at: <http://www.ncbi.nlm.nih.gov/pubmed/19555996>.

177. Touboul C, Uzan C, Mauguen A, et al. Prognostic factors and morbidities after completion surgery in patients undergoing initial chemoradiation therapy for locally advanced cervical cancer. *Oncologist* 2010;15:405-415. Available at: <http://www.ncbi.nlm.nih.gov/pubmed/20332143>.

178. Huguet F, Cojocariu OM, Levy P, et al. Preoperative concurrent radiation therapy and chemotherapy for bulky stage IB2, IIA, and IIB carcinoma of the uterine cervix with proximal parametrial invasion. *Int J Radiat Oncol Biol Phys* 2008;72:1508-1515. Available at: <http://www.ncbi.nlm.nih.gov/pubmed/18676093>.

179. Cetina L, Gonzalez-Enciso A, Cantu D, et al. Brachytherapy versus radical hysterectomy after external beam chemoradiation with gemcitabine plus cisplatin: a randomized, phase III study in IB2-IIB

cervical cancer patients. *Ann Oncol* 2013;24:2043-2047. Available at: <http://www.ncbi.nlm.nih.gov/pubmed/23609186>.

180. Kohler C, Mustea A, Marnitz S, et al. Perioperative morbidity and rate of upstaging after laparoscopic staging for patients with locally advanced cervical cancer: results of a prospective randomized trial. *Am J Obstet Gynecol* 2015;213:503 e501-507. Available at: <http://www.ncbi.nlm.nih.gov/pubmed/25986030>.

181. Goff BA, Muntz HG, Paley PJ, et al. Impact of surgical staging in women with locally advanced cervical cancer. *Gynecol Oncol* 1999;74:436-442. Available at: <http://www.ncbi.nlm.nih.gov/pubmed/10479506>.

182. Rose PG. Combination therapy: New treatment paradigm for locally advanced cervical cancer? *Nat Rev Clin Oncol* 2011;8:388-390. Available at: <http://www.ncbi.nlm.nih.gov/pubmed/21629215>.

183. Duenas-Gonzalez A, Zarba JJ, Patel F, et al. Phase III, open-label, randomized study comparing concurrent gemcitabine plus cisplatin and radiation followed by adjuvant gemcitabine and cisplatin versus concurrent cisplatin and radiation in patients with stage IIB to IVA carcinoma of the cervix. *J Clin Oncol* 2011;29:1678-1685. Available at: <http://www.ncbi.nlm.nih.gov/pubmed/21444871>.

184. Thomas G. Are we making progress in curing advanced cervical cancer? *J Clin Oncol* 2011;29:1654-1656. Available at: <http://www.ncbi.nlm.nih.gov/pubmed/21444860>.

185. Swisher EM, Swensen RE, Greer B, et al. Weekly gemcitabine and cisplatin in combination with pelvic radiation in the primary therapy of cervical cancer: a phase I trial of the Puget Sound Oncology Consortium. *Gynecol Oncol* 2006;101:429-435. Available at: <http://www.ncbi.nlm.nih.gov/pubmed/16337995>.

186. Rose PG, Degeest K, McMeekin S, Fusco N. A phase I study of gemcitabine followed by cisplatin concurrent with whole pelvic radiation therapy in locally advanced cervical cancer: a Gynecologic Oncology

Group study. *Gynecol Oncol* 2007;107:274-279. Available at: <http://www.ncbi.nlm.nih.gov/pubmed/17688925>.

187. Lutz ST, Chow EL, Hartsell WF, Konski AA. A review of hypofractionated palliative radiotherapy. *Cancer* 2007;109:1462-1470. Available at: <http://www.ncbi.nlm.nih.gov/pubmed/17330854>.

188. Rotman M, Sedlis A, Piedmonte MR, et al. A phase III randomized trial of postoperative pelvic irradiation in Stage IB cervical carcinoma with poor prognostic features: follow-up of a gynecologic oncology group study. *Int J Radiat Oncol Biol Phys* 2006;65:169-176. Available at: <http://www.ncbi.nlm.nih.gov/pubmed/16427212>.

189. Monk BJ, Wang J, Im S, et al. Rethinking the use of radiation and chemotherapy after radical hysterectomy: a clinical-pathologic analysis of a Gynecologic Oncology Group/Southwest Oncology Group/Radiation Therapy Oncology Group trial. *Gynecol Oncol* 2005;96:721-728. Available at: <http://www.ncbi.nlm.nih.gov/pubmed/15721417>.

190. Chernofsky MR, Felix JC, Muderspach LI, et al. Influence of quantity of lymph vascular space invasion on time to recurrence in women with early-stage squamous cancer of the cervix. *Gynecol Oncol* 2006;100:288-293. Available at: <http://www.ncbi.nlm.nih.gov/pubmed/16182347>.

191. Marchiole P, Buenerd A, Benchaib M, et al. Clinical significance of lympho vascular space involvement and lymph node micrometastases in early-stage cervical cancer: a retrospective case-control surgico-pathological study. *Gynecol Oncol* 2005;97:727-732. Available at: <http://www.ncbi.nlm.nih.gov/pubmed/15943983>.

192. Sedlis A, Bundy BN, Rotman MZ, et al. A randomized trial of pelvic radiation therapy versus no further therapy in selected patients with stage IB carcinoma of the cervix after radical hysterectomy and pelvic lymphadenectomy: A Gynecologic Oncology Group Study. *Gynecol Oncol* 1999;73:177-183. Available at: <http://www.ncbi.nlm.nih.gov/pubmed/10329031>.

193. Ryu SY, Kim MH, Nam BH, et al. Intermediate-risk grouping of cervical cancer patients treated with radical hysterectomy: a Korean Gynecologic Oncology Group study. *Br J Cancer* 2014;110:278-285. Available at: <http://www.ncbi.nlm.nih.gov/pubmed/24357798>.

194. Noh JM, Park W, Kim YS, et al. Comparison of clinical outcomes of adenocarcinoma and adenosquamous carcinoma in uterine cervical cancer patients receiving surgical resection followed by radiotherapy: a multicenter retrospective study (KROG 13-10). *Gynecol Oncol* 2014;132:618-623. Available at: <http://www.ncbi.nlm.nih.gov/pubmed/24486605>.

195. Estape RE, Angioli R, Madrigal M, et al. Close vaginal margins as a prognostic factor after radical hysterectomy. *Gynecol Oncol* 1998;68:229-232. Available at: <http://www.ncbi.nlm.nih.gov/pubmed/9570971>.

196. Trifiletti DM, Swisher-McClure S, Showalter TN, et al. Postoperative Chemoradiation Therapy in High-Risk Cervical Cancer: Re-evaluating the Findings of Gynecologic Oncology Group Study 109 in a Large, Population-Based Cohort. *Int J Radiat Oncol Biol Phys* 2015;93:1032-1044. Available at:

197. Gong L, Lou JY, Wang P, et al. Clinical evaluation of neoadjuvant chemotherapy followed by radical surgery in the management of stage IB2-IIB cervical cancer. *Int J Gynaecol Obstet* 2012;117:23-26. Available at: <http://www.ncbi.nlm.nih.gov/pubmed/22265255>.

198. Eddy GL, Bundy BN, Creasman WT, et al. Treatment of ("bulky") stage IB cervical cancer with or without neoadjuvant vincristine and cisplatin prior to radical hysterectomy and pelvic/para-aortic lymphadenectomy: a phase III trial of the gynecologic oncology group. *Gynecol Oncol* 2007;106:362-369. Available at: <http://www.ncbi.nlm.nih.gov/pubmed/17493669>.

199. Rydzewska L, Tierney J, Vale CL, Symonds PR. Neoadjuvant chemotherapy plus surgery versus surgery for cervical cancer.



Cochrane Database Syst Rev 2010:CD007406. Available at:

<http://www.ncbi.nlm.nih.gov/pubmed/20091632>.

200. Katsumata N, Yoshikawa H, Kobayashi H, et al. Phase III randomised controlled trial of neoadjuvant chemotherapy plus radical surgery vs radical surgery alone for stages IB2, IIA2, and IIB cervical cancer: a Japan Clinical Oncology Group trial (JCOG 0102). *Br J Cancer* 2013;108:1957-1963. Available at:

<http://www.ncbi.nlm.nih.gov/pubmed/23640393>.

201. Kim HS, Sardi JE, Katsumata N, et al. Efficacy of neoadjuvant chemotherapy in patients with FIGO stage IB1 to IIA cervical cancer: an international collaborative meta-analysis. *Eur J Surg Oncol* 2013;39:115-124. Available at:

<http://www.ncbi.nlm.nih.gov/pubmed/23084091>.

202. Landoni F, Sartori E, Maggino T, et al. Is there a role for postoperative treatment in patients with stage Ib2-IIb cervical cancer treated with neo-adjuvant chemotherapy and radical surgery? An Italian multicenter retrospective study. *Gynecol Oncol* 2014;132:611-617. Available at:

<http://www.ncbi.nlm.nih.gov/pubmed/24342439>.

203. Ye Q, Yuan HX, Chen HL. Responsiveness of neoadjuvant chemotherapy before surgery predicts favorable prognosis for cervical cancer patients: a meta-analysis. *J Cancer Res Clin Oncol* 2013;139:1887-1898. Available at:

<http://www.ncbi.nlm.nih.gov/pubmed/24022086>.

204. Salani R, Backes FJ, Fung MF, et al. Posttreatment surveillance and diagnosis of recurrence in women with gynecologic malignancies: Society of Gynecologic Oncologists recommendations. *Am J Obstet Gynecol* 2011;204:466-478. Available at:

<http://www.ncbi.nlm.nih.gov/pubmed/21752752>.

205. Bodurka-Bevers D, Morris M, Eifel PJ, et al. Posttherapy surveillance of women with cervical cancer: an outcomes analysis. *Gynecol Oncol* 2000;78:187-193. Available at:

<http://www.ncbi.nlm.nih.gov/pubmed/10926801>.

206. Morice P, Deyrolle C, Rey A, et al. Value of routine follow-up procedures for patients with stage I/II cervical cancer treated with combined surgery-radiation therapy. *Ann Oncol* 2004;15:218-223. Available at:

<http://www.ncbi.nlm.nih.gov/pubmed/14760112>.

207. Elit L, Fyles AW, Devries MC, et al. Follow-up for women after treatment for cervical cancer: a systematic review. *Gynecol Oncol* 2009;114:528-535. Available at:

<http://www.ncbi.nlm.nih.gov/pubmed/19560188>.

208. Sala E, Micco M, Burger IA, et al. Complementary Prognostic Value of Pelvic Magnetic Resonance Imaging and Whole-Body Fluorodeoxyglucose Positron Emission Tomography/Computed Tomography in the Pretreatment Assessment of Patients With Cervical Cancer. *Int J Gynecol Cancer* 2015;25:1461-1467. Available at:

<http://www.ncbi.nlm.nih.gov/pubmed/26397068>.

209. Balleyguier C, Sala E, Da Cunha T, et al. Staging of uterine cervical cancer with MRI: guidelines of the European Society of Urogenital Radiology. *Eur Radiol* 2011;21:1102-1110. Available at:

<http://www.ncbi.nlm.nih.gov/pubmed/21063710>.

210. Sala E, Rockall AG, Freeman SJ, et al. The added role of MR imaging in treatment stratification of patients with gynecologic malignancies: what the radiologist needs to know. *Radiology* 2013;266:717-740. Available at:

<http://www.ncbi.nlm.nih.gov/pubmed/23431227>.

211. Elit L, Reade CJ. Recommendations for Follow-up Care for Gynecologic Cancer Survivors. *Obstet Gynecol* 2015;126:1207-1214. Available at:

<http://www.ncbi.nlm.nih.gov/pubmed/26551194>.

212. Rajendran JG, Greer BE. Expanding role of positron emission tomography in cancer of the uterine cervix. *J Natl Compr Canc Netw* 2006;4:463-469. Available at:

<http://www.ncbi.nlm.nih.gov/pubmed/16687094>.

213. Atri M, Zhang Z, Dehdashti F, et al. Utility of PET-CT to evaluate retroperitoneal lymph node metastasis in advanced cervical cancer: Results of ACRIN6671/GOG0233 trial. *Gynecol Oncol* 2016;142:413-419. Available at: <http://www.ncbi.nlm.nih.gov/pubmed/27178725>.
214. Brooks RA, Rader JS, Dehdashti F, et al. Surveillance FDG-PET detection of asymptomatic recurrences in patients with cervical cancer. *Gynecol Oncol* 2009;112:104-109. Available at: <http://www.ncbi.nlm.nih.gov/pubmed/18929403>.
215. Schwarz JK, Siegel BA, Dehdashti F, Grigsby PW. Association of posttherapy positron emission tomography with tumor response and survival in cervical carcinoma. *JAMA* 2007;298:2289-2295. Available at: <http://www.ncbi.nlm.nih.gov/pubmed/18029833>.
216. Sironi S, Picchio M, Landoni C, et al. Post-therapy surveillance of patients with uterine cancers: value of integrated FDG PET/CT in the detection of recurrence. *Eur J Nucl Med Mol Imaging* 2007;34:472-479. Available at: <http://www.ncbi.nlm.nih.gov/pubmed/17106701>.
217. Chung HH, Jo H, Kang WJ, et al. Clinical impact of integrated PET/CT on the management of suspected cervical cancer recurrence. *Gynecol Oncol* 2007;104:529-534. Available at: <http://www.ncbi.nlm.nih.gov/pubmed/17049971>.
218. Wolfson AH, Varia MA, Moore D, et al. ACR Appropriateness Criteria(R) role of adjuvant therapy in the management of early stage cervical cancer. *Gynecol Oncol* 2012;125:256-262. Available at: <http://www.ncbi.nlm.nih.gov/pubmed/22155418>.
219. Chaturvedi AK, Kleinerman RA, Hildesheim A, et al. Second cancers after squamous cell carcinoma and adenocarcinoma of the cervix. *J Clin Oncol* 2009;27:967-973. Available at: <http://www.ncbi.nlm.nih.gov/pubmed/19114696>.
220. Chaturvedi AK, Engels EA, Gilbert ES, et al. Second cancers among 104,760 survivors of cervical cancer: evaluation of long-term risk. *J Natl Cancer Inst* 2007;99:1634-1643. Available at: <http://www.ncbi.nlm.nih.gov/pubmed/17971527>.
221. Kumar S, Shah JP, Bryant CS, et al. Radiation-associated endometrial cancer. *Obstet Gynecol* 2009;113:319-325. Available at: <http://www.ncbi.nlm.nih.gov/pubmed/19155901>.
222. Hong JH, Tsai CS, Lai CH, et al. Recurrent squamous cell carcinoma of cervix after definitive radiotherapy. *Int J Radiat Oncol Biol Phys* 2004;60:249-257. Available at: <http://www.ncbi.nlm.nih.gov/pubmed/15337563>.
223. Thomas GM, Dembo AJ, Myhr T, et al. Long-term results of concurrent radiation and chemotherapy for carcinoma of the cervix recurrent after surgery. *Int J Gynecol Cancer* 1993;3:193-198. Available at: <http://www.ncbi.nlm.nih.gov/pubmed/11578344>.
224. Kim JS, Kim SY, Kim KH, Cho MJ. Hyperfractionated radiotherapy with concurrent chemotherapy for para-aortic lymph node recurrence in carcinoma of the cervix. *Int J Radiat Oncol Biol Phys* 2003;55:1247-1253. Available at: <http://www.ncbi.nlm.nih.gov/pubmed/12654434>.
225. Chung YL, Jian JJ, Cheng SH, et al. Extended-field radiotherapy and high-dose-rate brachytherapy with concurrent and adjuvant cisplatin-based chemotherapy for locally advanced cervical cancer: a phase I/II study. *Gynecol Oncol* 2005;97:126-135. Available at: <http://www.ncbi.nlm.nih.gov/pubmed/15790448>.
226. Marnitz S, Dowdy S, Lanowska M, et al. Exenterations 60 years after first description: results of a survey among US and German Gynecologic Oncology Centers. *Int J Gynecol Cancer* 2009;19:974-977. Available at: <http://www.ncbi.nlm.nih.gov/pubmed/19574795>.
227. Berek JS, Howe C, Lagasse LD, Hacker NF. Pelvic exenteration for recurrent gynecologic malignancy: survival and morbidity analysis of the 45-year experience at UCLA. *Gynecol Oncol* 2005;99:153-159. Available at: <http://www.ncbi.nlm.nih.gov/pubmed/16054678>.

228. Goldberg GL, Sukumvanich P, Einstein MH, et al. Total pelvic exenteration: the Albert Einstein College of Medicine/Montefiore Medical Center Experience (1987 to 2003). *Gynecol Oncol* 2006;101:261-268. Available at: <http://www.ncbi.nlm.nih.gov/pubmed/16426668>.

229. Morley GW, Hopkins MP, Lindenauer SM, Roberts JA. Pelvic exenteration, University of Michigan: 100 patients at 5 years. *Obstet Gynecol* 1989;74:934-943. Available at: <http://www.ncbi.nlm.nih.gov/pubmed/2586960>.

230. Fleisch MC, Pantke P, Beckmann MW, et al. Predictors for long-term survival after interdisciplinary salvage surgery for advanced or recurrent gynecologic cancers. *J Surg Oncol* 2007;95:476-484. Available at: <http://www.ncbi.nlm.nih.gov/pubmed/17192947>.

231. Tran PT, Su Z, Hara W, et al. Long-term survivors using intraoperative radiotherapy for recurrent gynecologic malignancies. *Int J Radiat Oncol Biol Phys* 2007;69:504-511. Available at: <http://www.ncbi.nlm.nih.gov/pubmed/17560736>.

232. Rutledge FN, Smith JP, Wharton JT, O'Quinn AG. Pelvic exenteration: analysis of 296 patients. *Am J Obstet Gynecol* 1977;129:881-892. Available at: <http://www.ncbi.nlm.nih.gov/pubmed/930972>.

233. Symmonds RE, Pratt JH, Webb MJ. Exenterative operations: experience with 198 patients. *Am J Obstet Gynecol* 1975;121:907-918. Available at: <http://www.ncbi.nlm.nih.gov/pubmed/1115180>.

234. Soper JT, Secord AA, Havrilesky LJ, et al. Comparison of gracilis and rectus abdominis myocutaneous flap neovaginal reconstruction performed during radical pelvic surgery: flap-specific morbidity. *Int J Gynecol Cancer* 2007;17:298-303. Available at: <http://www.ncbi.nlm.nih.gov/pubmed/17291272>.

235. Mirhashemi R, Averette HE, Lambrou N, et al. Vaginal reconstruction at the time of pelvic exenteration: a surgical and

psychosexual analysis of techniques. *Gynecol Oncol* 2002;87:39-45. Available at: <http://www.ncbi.nlm.nih.gov/pubmed/12468340>.

236. Turns D. Psychosocial issues: pelvic exenterative surgery. *J Surg Oncol* 2001;76:224-236. Available at: <http://www.ncbi.nlm.nih.gov/pubmed/11276026>.

237. Smith SC, Koh WJ. Palliative radiation therapy for gynaecological malignancies. *Best Pract Res Clin Obstet Gynaecol* 2001;15:265-278. Available at: <http://www.ncbi.nlm.nih.gov/pubmed/11358401>.

238. Spanos WJ, Jr., Perez CA, Marcus S, et al. Effect of rest interval on tumor and normal tissue response--a report of phase III study of accelerated split course palliative radiation for advanced pelvic malignancies (RTOG-8502). *Int J Radiat Oncol Biol Phys* 1993;25:399-403. Available at: <http://www.ncbi.nlm.nih.gov/pubmed/7679668>.

239. Moore DH, Blessing JA, McQuellon RP, et al. Phase III study of cisplatin with or without paclitaxel in stage IVB, recurrent, or persistent squamous cell carcinoma of the cervix: a gynecologic oncology group study. *J Clin Oncol* 2004;22:3113-3119. Available at: <http://www.ncbi.nlm.nih.gov/pubmed/15284262>.

240. Long HJ, 3rd, Bundy BN, Grendys EC, Jr., et al. Randomized phase III trial of cisplatin with or without topotecan in carcinoma of the uterine cervix: a Gynecologic Oncology Group Study. *J Clin Oncol* 2005;23:4626-4633. Available at: <http://www.ncbi.nlm.nih.gov/pubmed/15911865>.

241. Thigpen T, Shingleton H, Homesley H, et al. Cis-platinum in treatment of advanced or recurrent squamous cell carcinoma of the cervix: a phase II study of the Gynecologic Oncology Group. *Cancer* 1981;48:899-903. Available at: <http://www.ncbi.nlm.nih.gov/pubmed/7196794>.

242. Moore DH. Chemotherapy for advanced, recurrent, and metastatic cervical cancer. *J Natl Compr Canc Netw* 2008;6:53-57. Available at: <http://www.ncbi.nlm.nih.gov/pubmed/18267059>.

243. Tao X, Hu W, Ramirez PT, Kavanagh JJ. Chemotherapy for recurrent and metastatic cervical cancer. *Gynecol Oncol* 2008;110:67-71. Available at: <http://www.ncbi.nlm.nih.gov/pubmed/18533239>.

244. Monk BJ, Sill MW, McMeekin DS, et al. Phase III trial of four cisplatin-containing doublet combinations in stage IVB, recurrent, or persistent cervical carcinoma: a Gynecologic Oncology Group study. *J Clin Oncol* 2009;27:4649-4655. Available at: <http://www.ncbi.nlm.nih.gov/pubmed/19720909>.

245. Tewari KS, Sill MW, Long HJ, 3rd, et al. Improved survival with bevacizumab in advanced cervical cancer. *N Engl J Med* 2014;370:734-743. Available at: <http://www.ncbi.nlm.nih.gov/pubmed/24552320>.

246. Zigelboim I, Wright JD, Gao F, et al. Multicenter phase II trial of topotecan, cisplatin and bevacizumab for recurrent or persistent cervical cancer. *Gynecol Oncol* 2013;130:64-68. Available at: <http://www.ncbi.nlm.nih.gov/pubmed/23591400>.

247. Penson RT, Huang HQ, Wenzel LB, et al. Bevacizumab for advanced cervical cancer: patient-reported outcomes of a randomised, phase 3 trial (NRG Oncology-Gynecologic Oncology Group protocol 240). *Lancet Oncol* 2015;16:301-311. Available at: <http://www.ncbi.nlm.nih.gov/pubmed/25638326>.

248. National Cancer Institute. FDA Approval for Bevacizumab. 2014. Available at: <http://www.cancer.gov/cancertopics/druginfo/fda-bevacizumab>. Accessed August 29, 2014.

249. Kitagawa R, Katsumata N, Shibata T, et al. Paclitaxel Plus Carboplatin Versus Paclitaxel Plus Cisplatin in Metastatic or Recurrent Cervical Cancer: The Open-Label Randomized Phase III Trial JCOG0505. *J Clin Oncol* 2015;33:2129-2135. Available at: <http://www.ncbi.nlm.nih.gov/pubmed/25732161>.

250. Moore KN, Herzog TJ, Lewin S, et al. A comparison of cisplatin/paclitaxel and carboplatin/paclitaxel in stage IVB, recurrent or

persistent cervical cancer. *Gynecol Oncol* 2007;105:299-303. Available at: <http://www.ncbi.nlm.nih.gov/pubmed/17303230>.

251. Lorusso D, Petrelli F, Coinu A, et al. A systematic review comparing cisplatin and carboplatin plus paclitaxel-based chemotherapy for recurrent or metastatic cervical cancer. *Gynecol Oncol* 2014;133:117-123. Available at: <http://www.ncbi.nlm.nih.gov/pubmed/24486604>.

252. Leath CA, 3rd, Straughn JM, Jr. Chemotherapy for advanced and recurrent cervical carcinoma: results from cooperative group trials. *Gynecol Oncol* 2013;129:251-257. Available at: <http://www.ncbi.nlm.nih.gov/pubmed/23280089>.

253. Thigpen JT, Blessing JA, DiSaia PJ, et al. A randomized comparison of a rapid versus prolonged (24 hr) infusion of cisplatin in therapy of squamous cell carcinoma of the uterine cervix: a Gynecologic Oncology Group study. *Gynecol Oncol* 1989;32:198-202. Available at: <http://www.ncbi.nlm.nih.gov/pubmed/2910782>.

254. Pectasides D, Kamposioras K, Papaxoinis G, Pectasides E. Chemotherapy for recurrent cervical cancer. *Cancer Treat Rev* 2008;34:603-613. Available at: <http://www.ncbi.nlm.nih.gov/pubmed/18657909>.

255. McGuire WP, Arseneau J, Blessing JA, et al. A randomized comparative trial of carboplatin and iproplatin in advanced squamous carcinoma of the uterine cervix: a Gynecologic Oncology Group study. *J Clin Oncol* 1989;7:1462-1468. Available at: <http://www.ncbi.nlm.nih.gov/pubmed/2674333>.

256. Weiss GR, Green S, Hannigan EV, et al. A phase II trial of carboplatin for recurrent or metastatic squamous carcinoma of the uterine cervix: a Southwest Oncology Group study. *Gynecol Oncol* 1990;39:332-336. Available at: <http://www.ncbi.nlm.nih.gov/pubmed/2258080>.



257. Kudelka AP, Winn R, Edwards CL, et al. An update of a phase II study of paclitaxel in advanced or recurrent squamous cell cancer of the cervix. *Anticancer Drugs* 1997;8:657-661. Available at: <http://www.ncbi.nlm.nih.gov/pubmed/9311440>.
258. McGuire WP, Blessing JA, Moore D, et al. Paclitaxel has moderate activity in squamous cervix cancer. A Gynecologic Oncology Group study. *J Clin Oncol* 1996;14:792-795. Available at: <http://www.ncbi.nlm.nih.gov/pubmed/8622025>.
259. Monk BJ, Sill MW, Burger RA, et al. Phase II trial of bevacizumab in the treatment of persistent or recurrent squamous cell carcinoma of the cervix: a gynecologic oncology group study. *J Clin Oncol* 2009;27:1069-1074. Available at: <http://www.ncbi.nlm.nih.gov/pubmed/19139430>.
260. Garcia AA, Blessing JA, Vaccarello L, Roman LD. Phase II clinical trial of docetaxel in refractory squamous cell carcinoma of the cervix: a Gynecologic Oncology Group Study. *Am J Clin Oncol* 2007;30:428-431. Available at: <http://www.ncbi.nlm.nih.gov/pubmed/17762444>.
261. Look KY, Blessing JA, Gallup DG, Lentz SS. A phase II trial of 5-fluorouracil and high-dose leucovorin in patients with recurrent squamous cell carcinoma of the cervix: a Gynecologic Oncology Group study. *Am J Clin Oncol* 1996;19:439-441. Available at: <http://www.ncbi.nlm.nih.gov/pubmed/8823469>.
262. Schilder RJ, Blessing J, Cohn DE. Evaluation of gemcitabine in previously treated patients with non-squamous cell carcinoma of the cervix: a phase II study of the Gynecologic Oncology Group. *Gynecol Oncol* 2005;96:103-107. Available at: <http://www.ncbi.nlm.nih.gov/pubmed/15589587>.
263. Coleman RE, Harper PG, Gallagher C, et al. A phase II study of ifosfamide in advanced and relapsed carcinoma of the cervix. *Cancer Chemother Pharmacol* 1986;18:280-283. Available at: <http://www.ncbi.nlm.nih.gov/pubmed/3802384>.
264. Sutton GP, Blessing JA, McGuire WP, et al. Phase II trial of ifosfamide and mesna in patients with advanced or recurrent squamous carcinoma of the cervix who had never received chemotherapy: a Gynecologic Oncology Group study. *Am J Obstet Gynecol* 1993;168:805-807. Available at: <http://www.ncbi.nlm.nih.gov/pubmed/8456884>.
265. Verschraegen CF, Levy T, Kudelka AP, et al. Phase II study of irinotecan in prior chemotherapy-treated squamous cell carcinoma of the cervix. *J Clin Oncol* 1997;15:625-631. Available at: <http://www.ncbi.nlm.nih.gov/pubmed/9053486>.
266. Wagenaar HC, Pecorelli S, Mangioni C, et al. Phase II study of mitomycin-C and cisplatin in disseminated, squamous cell carcinoma of the uterine cervix. A European Organization for Research and Treatment of Cancer (EORTC) Gynecological Cancer Group study. *Eur J Cancer* 2001;37:1624-1628. Available at: <http://www.ncbi.nlm.nih.gov/pubmed/11527687>.
267. Alberts DS, Blessing JA, Landrum LM, et al. Phase II trial of nab-paclitaxel in the treatment of recurrent or persistent advanced cervix cancer: A gynecologic oncology group study. *Gynecol Oncol* 2012;127:451-455. Available at: <http://www.ncbi.nlm.nih.gov/pubmed/22986144>.
268. Bookman MA, Blessing JA, Hanjani P, et al. Topotecan in squamous cell carcinoma of the cervix: A Phase II study of the Gynecologic Oncology Group. *Gynecol Oncol* 2000;77:446-449. Available at: <http://www.ncbi.nlm.nih.gov/pubmed/10831357>.
269. Muderspach LI, Blessing JA, Levenback C, Moore JL. A Phase II study of topotecan in patients with squamous cell carcinoma of the cervix: a gynecologic oncology group study. *Gynecol Oncol* 2001;81:213-215. Available at: <http://www.ncbi.nlm.nih.gov/pubmed/11354055>.
270. Miller DS, Blessing JA, Bodurka DC, et al. Evaluation of pemetrexed (Alimta, LY231514) as second line chemotherapy in

persistent or recurrent carcinoma of the cervix: a phase II study of the Gynecologic Oncology Group. *Gynecol Oncol* 2008;110:65-70. Available at: <http://www.ncbi.nlm.nih.gov/pubmed/18455781>.

271. Muggia FM, Blessing JA, Method M, et al. Evaluation of vinorelbine in persistent or recurrent squamous cell carcinoma of the cervix: a Gynecologic Oncology Group study. *Gynecol Oncol* 2004;92:639-643. Available at: <http://www.ncbi.nlm.nih.gov/pubmed/14766259>.

272. Castells MC, Tennant NM, Sloane DE, et al. Hypersensitivity reactions to chemotherapy: outcomes and safety of rapid desensitization in 413 cases. *J Allergy Clin Immunol* 2008;122:574-580. Available at: <http://www.ncbi.nlm.nih.gov/pubmed/18502492>.

273. Sampson HA, Munoz-Furlong A, Campbell RL, et al. Second symposium on the definition and management of anaphylaxis: summary report--second National Institute of Allergy and Infectious Disease/Food Allergy and Anaphylaxis Network symposium. *Ann Emerg Med* 2006;47:373-380. Available at: <http://www.ncbi.nlm.nih.gov/pubmed/16546624>.

274. Manivannan V, Decker WW, Stead LG, et al. Visual representation of National Institute of Allergy and Infectious Disease and Food Allergy and Anaphylaxis Network criteria for anaphylaxis. *Int J Emerg Med* 2009;2:3-5. Available at: <http://www.ncbi.nlm.nih.gov/pubmed/19390910>.

275. Lenz HJ. Management and preparedness for infusion and hypersensitivity reactions. *Oncologist* 2007;12:601-609. Available at: <http://www.ncbi.nlm.nih.gov/pubmed/17522249>.

276. Markman M, Zanotti K, Peterson G, et al. Expanded experience with an intradermal skin test to predict for the presence or absence of carboplatin hypersensitivity. *J Clin Oncol* 2003;21:4611-4614. Available at: <http://www.ncbi.nlm.nih.gov/pubmed/14673050>.

277. Lee CW, Matulonis UA, Castells MC. Rapid inpatient/outpatient desensitization for chemotherapy hypersensitivity: standard protocol

effective in 57 patients for 255 courses. *Gynecol Oncol* 2005;99:393-399. Available at: <http://www.ncbi.nlm.nih.gov/pubmed/16054201>.

278. Lee CW, Matulonis UA, Castells MC. Carboplatin hypersensitivity: a 6-h 12-step protocol effective in 35 desensitizations in patients with gynecological malignancies and mast cell/IgE-mediated reactions. *Gynecol Oncol* 2004;95:370-376. Available at: <http://www.ncbi.nlm.nih.gov/pubmed/15491759>.

279. Monie A, Tsen S-WD, Hung C-F, Wu TC. Therapeutic HPV DNA vaccines. *Expert Rev Vaccines* 2009;8:1221-1235. Available at: <http://www.ncbi.nlm.nih.gov/pubmed/19722895>.

280. Hung C-F, Ma B, Monie A, et al. Therapeutic human papillomavirus vaccines: current clinical trials and future directions. *Expert Opin Biol Ther* 2008;8:421-439. Available at: <http://www.ncbi.nlm.nih.gov/pubmed/18352847>.

281. Huang CF, Monie A, Weng WH, Wu T. DNA vaccines for cervical cancer. *Am J Transl Res* 2010;2:75-87. Available at: <http://www.ncbi.nlm.nih.gov/pubmed/20182584>.

282. Gonzalez-Cortijo L, Carballo N, Gonzalez-Martin A, et al. Novel chemotherapy approaches in chemoradiation protocols. *Gynecol Oncol* 2008;110:S45-48. Available at: <http://www.ncbi.nlm.nih.gov/pubmed/18678399>.

283. Poveda A, Gonzalez-Martin A. Multimodality treatment in locoregional gynecological cancer: cervical cancer treatment update. *Ann Oncol* 2008;19 Suppl 7:vii70-76. Available at: <http://www.ncbi.nlm.nih.gov/pubmed/18790983>.

284. Gonzalez Martin A. Molecular biology of cervical cancer. *Clin Transl Oncol* 2007;9:347-354. Available at: <http://www.ncbi.nlm.nih.gov/pubmed/17594948>.

285. Tinker AV, Ellard S, Welch S, et al. Phase II study of temsirolimus (CCI-779) in women with recurrent, unresectable, locally advanced or



metastatic carcinoma of the cervix. A trial of the NCIC Clinical Trials Group (NCIC CTG IND 199). *Gynecol Oncol* 2013;130:269-274. Available at: <http://www.ncbi.nlm.nih.gov/pubmed/23672928>.

286. Nogueira-Rodrigues A, do Carmo CC, Viegas C, et al. Phase I trial of erlotinib combined with cisplatin and radiotherapy for patients with locally advanced cervical squamous cell cancer. *Clin Cancer Res* 2008;14:6324-6329. Available at: <http://www.ncbi.nlm.nih.gov/pubmed/18829516>.

287. Nogueira-Rodrigues A, Moralez G, Grazziotin R, et al. Phase 2 trial of erlotinib combined with cisplatin and radiotherapy in patients with locally advanced cervical cancer. *Cancer* 2014;120:1187-1193. Available at: <http://www.ncbi.nlm.nih.gov/pubmed/24615735>.

288. Higginson DS, Morris DE, Jones EL, et al. Stereotactic body radiotherapy (SBRT): Technological innovation and application in gynecologic oncology. *Gynecol Oncol* 2011;120:404-412. Available at: <http://www.ncbi.nlm.nih.gov/pubmed/21194733>.

289. Choi CW, Cho CK, Yoo SY, et al. Image-guided stereotactic body radiation therapy in patients with isolated para-aortic lymph node metastases from uterine cervical and corpus cancer. *Int J Radiat Oncol Biol Phys* 2009;74:147-153. Available at: <http://www.ncbi.nlm.nih.gov/pubmed/18990511>.

290. Jadon R, Pembroke CA, Hanna CL, et al. A systematic review of organ motion and image-guided strategies in external beam radiotherapy for cervical cancer. *Clin Oncol (R Coll Radiol)* 2014;26:185-196. Available at: <http://www.ncbi.nlm.nih.gov/pubmed/24566332>.

291. Eminowicz G, Hall-Craggs M, Diez P, McCormack M. Improving target volume delineation in intact cervical carcinoma: Literature review and step-by-step pictorial atlas to aid contouring. *Pract Radiat Oncol* 2016;6:e203-213. Available at: <https://www.ncbi.nlm.nih.gov/pubmed/27032573>.

292. Klopp AH, Yeung AR, Deshmukh S, et al. A Phase III Randomized Trial Comparing Patient-Reported Toxicity and Quality of Life (QOL) During Pelvic Intensity Modulated Radiation Therapy as Compared to Conventional Radiation Therapy. *Int J Radiat Oncol Biol Phys* 2016;96:S3. Available at: <https://www.ncbi.nlm.nih.gov/pubmed/27675895>.

293. Potter R, Georg P, Dimopoulos JC, et al. Clinical outcome of protocol based image (MRI) guided adaptive brachytherapy combined with 3D conformal radiotherapy with or without chemotherapy in patients with locally advanced cervical cancer. *Radiother Oncol* 2011;100:116-123. Available at: <http://www.ncbi.nlm.nih.gov/pubmed/21821305>.

294. Haie-Meder C, Potter R, Van Limbergen E, et al. Recommendations from Gynaecological (GYN) GEC-ESTRO Working Group (I): concepts and terms in 3D image based 3D treatment planning in cervix cancer brachytherapy with emphasis on MRI assessment of GTV and CTV. *Radiother Oncol* 2005;74:235-245. Available at: <http://www.ncbi.nlm.nih.gov/pubmed/15763303>.

295. Yoshida K, Jastaniyah N, Sturdza A, et al. Assessment of Parametrial Response by Growth Pattern in Patients With International Federation of Gynecology and Obstetrics Stage IIB and IIIB Cervical Cancer: Analysis of Patients From a Prospective, Multicenter Trial (EMBRACE). *Int J Radiat Oncol Biol Phys* 2015;93:788-796. Available at: <http://www.ncbi.nlm.nih.gov/pubmed/26530747>.

296. Erickson-Whitmann B, Rownd J, Khater K. Biologic and physical aspects of radiation oncology. In: Barakat R, Markman M, Randall M, eds. *Principles and Practice of Gynecology Oncology*, 5th ed. Philadelphia: Lippincott Williams & Wilkins; 2009:325-380.

297. Lim K, Small W, Jr., Portelance L, et al. Consensus guidelines for delineation of clinical target volume for intensity-modulated pelvic radiotherapy for the definitive treatment of cervix cancer. *Int J Radiat Oncol Biol Phys* 2011;79:348-355. Available at: <http://www.ncbi.nlm.nih.gov/pubmed/20472347>.

298. Loisel C, Koh WJ. The emerging use of IMRT for treatment of cervical cancer. *J Natl Compr Canc Netw* 2010;8:1425-1434. Available at: <http://www.ncbi.nlm.nih.gov/pubmed/21147905>.
299. Beriwal S, Gan GN, Heron DE, et al. Early clinical outcome with concurrent chemotherapy and extended-field, intensity-modulated radiotherapy for cervical cancer. *Int J Radiat Oncol Biol Phys* 2007;68:166-171. Available at: <http://www.ncbi.nlm.nih.gov/pubmed/17321070>.
300. Chen M-F, Tseng C-J, Tseng C-C, et al. Clinical outcome in posthysterectomy cervical cancer patients treated with concurrent Cisplatin and intensity-modulated pelvic radiotherapy: comparison with conventional radiotherapy. *Int J Radiat Oncol Biol Phys* 2007;67:1438-1444. Available at: <http://www.ncbi.nlm.nih.gov/pubmed/17394944>.
301. Chen M-F, Tseng C-J, Tseng C-C, et al. Adjuvant concurrent chemoradiotherapy with intensity-modulated pelvic radiotherapy after surgery for high-risk, early stage cervical cancer patients. *Cancer J* 2008;14:200-206. Available at: <http://www.ncbi.nlm.nih.gov/pubmed/18536561>.
302. Salama JK, Mundt AJ, Roeske J, Mehta N. Preliminary outcome and toxicity report of extended-field, intensity-modulated radiation therapy for gynecologic malignancies. *Int J Radiat Oncol Biol Phys* 2006;65:1170-1176. Available at: <http://www.ncbi.nlm.nih.gov/pubmed/16730136>.
303. Small W, Mell LK, Anderson P, et al. Consensus guidelines for delineation of clinical target volume for intensity-modulated pelvic radiotherapy in postoperative treatment of endometrial and cervical cancer. *Int J Radiat Oncol Biol Phys* 2008;71:428-434. Available at: <http://www.ncbi.nlm.nih.gov/pubmed/18037584>.
304. Erpolat OP, Alco G, Caglar HB, et al. Comparison of hematologic toxicity between 3DCRT and IMRT planning in cervical cancer patients after concurrent chemoradiotherapy: a national multi-center study. *Eur J Gynaecol Oncol* 2014;35:62-66. Available at: <http://www.ncbi.nlm.nih.gov/pubmed/24654465>.
305. Klopp AH, Moughan J, Portelance L, et al. Hematologic toxicity in RTOG 0418: a phase 2 study of postoperative IMRT for gynecologic cancer. *Int J Radiat Oncol Biol Phys* 2013;86:83-90. Available at: <http://www.ncbi.nlm.nih.gov/pubmed/23582248>.
306. RTOG 1203 Protocol Information. Radiation Therapy Oncology Group; 2013. Available at: <http://www.rtog.org/ClinicalTrials/ProtocolTable/StudyDetails.aspx?study=1203>. Accessed July 28, 2014.
307. Fyles A, Keane TJ, Barton M, Simm J. The effect of treatment duration in the local control of cervix cancer. *Radiother Oncol* 1992;25:273-279. Available at: <http://www.ncbi.nlm.nih.gov/pubmed/1480773>.
308. Girinsky T, Rey A, Roche B, et al. Overall treatment time in advanced cervical carcinomas: a critical parameter in treatment outcome. *Int J Radiat Oncol Biol Phys* 1993;27:1051-1056. Available at: <http://www.ncbi.nlm.nih.gov/pubmed/8262826>.
309. Lanciano RM, Pajak TF, Martz K, Hanks GE. The influence of treatment time on outcome for squamous cell cancer of the uterine cervix treated with radiation: a patterns-of-care study. *Int J Radiat Oncol Biol Phys* 1993;25:391-397. Available at: <http://www.ncbi.nlm.nih.gov/pubmed/8436516>.
310. Perez CA, Grigsby PW, Castro-Vita H, Lockett MA. Carcinoma of the uterine cervix. I. Impact of prolongation of overall treatment time and timing of brachytherapy on outcome of radiation therapy. *Int J Radiat Oncol Biol Phys* 1995;32:1275-1288. Available at: <http://www.ncbi.nlm.nih.gov/pubmed/7635767>.
311. Petereit DG, Sarkaria JN, Chappell R, et al. The adverse effect of treatment prolongation in cervical carcinoma. *Int J Radiat Oncol Biol*

Phys 1995;32:1301-1307. Available at:  
<http://www.ncbi.nlm.nih.gov/pubmed/7635769>.

312. Eifel PJ, Levenback C, Wharton JT, Oswald MJ. Time course and incidence of late complications in patients treated with radiation therapy for FIGO stage IB carcinoma of the uterine cervix. *Int J Radiat Oncol Biol Phys* 1995;32:1289-1300. Available at:  
<http://www.ncbi.nlm.nih.gov/pubmed/7635768>.

313. Forrest JL, Ackerman I, Barbera L, et al. Patient outcome study of concurrent chemoradiation, external beam radiotherapy, and high-dose rate brachytherapy in locally advanced carcinoma of the cervix. *Int J Gynecol Cancer* 2010;20:1074-1078. Available at:  
<http://www.ncbi.nlm.nih.gov/pubmed/20683420>.

314. Perez CA, Grigsby PW, Lockett MA, et al. Radiation therapy morbidity in carcinoma of the uterine cervix: dosimetric and clinical correlation. *Int J Radiat Oncol Biol Phys* 1999;44:855-866. Available at:  
<http://www.ncbi.nlm.nih.gov/pubmed/10386643>.

315. Van Calsteren K, Heyns L, De Smet F, et al. Cancer during pregnancy: an analysis of 215 patients emphasizing the obstetrical and the neonatal outcomes. *J Clin Oncol* 2010;28:683-689. Available at:  
<http://www.ncbi.nlm.nih.gov/pubmed/19841323>.

316. Fukushima K, Ogawa S, Tsukimori K, et al. Can we diagnose invasive cervical cancer during pregnancy as precise as in nonpregnant women?: maternal and perinatal outcome in pregnancies complicated with cervical cancers. *Int J Gynecol Cancer* 2009;19:1439-1445. Available at: <http://www.ncbi.nlm.nih.gov/pubmed/20009904>.

317. Smith LH, Danielsen B, Allen ME, Cress R. Cancer associated with obstetric delivery: results of linkage with the California cancer registry. *Am J Obstet Gynecol* 2003;189:1128-1135. Available at:  
<http://www.ncbi.nlm.nih.gov/pubmed/14586366>.

318. Swenson RE, Goff BA, Koh W-J, et al. Cancer in the pregnant patient. In: Hoskins WJ, Perez CA, Young RC, eds. *Principles and*

*Practice of Gynecologic Oncology*, 4th ed. Philadelphia: Lippincott Williams & Wilkins; 2004 1279-1311.

319. Sadler L, Sykes P. How little is known about cervical cancer in pregnancy? *Ann Oncol* 2005;16:341-343. Available at:  
<http://www.ncbi.nlm.nih.gov/pubmed/15722461>.

320. Morice P, Narducci F, Mathevet P, et al. French recommendations on the management of invasive cervical cancer during pregnancy. *Int J Gynecol Cancer* 2009;19:1638-1641. Available at:  
<http://www.ncbi.nlm.nih.gov/pubmed/19955951>.

321. Sood AK, Sorosky JI. Invasive cervical cancer complicating pregnancy. How to manage the dilemma. *Obstet Gynecol Clin North Am* 1998;25:343-352. Available at:  
<http://www.ncbi.nlm.nih.gov/pubmed/9629575>.

322. van de Nieuwenhof HP, van Ham MAPC, Lotgering FK, Massuger LFAG. First case of vaginal radical trachelectomy in a pregnant patient. *Int J Gynecol Cancer* 2008;18:1381-1385. Available at:  
<http://www.ncbi.nlm.nih.gov/pubmed/18298565>.

323. Ben-Arie A, Levy R, Lavie O, et al. Conservative treatment of stage IA2 squamous cell carcinoma of the cervix during pregnancy. *Obstet Gynecol* 2004;104:1129-1131. Available at:  
<http://www.ncbi.nlm.nih.gov/pubmed/15516424>.

324. Gurney EP, Blank SV. Postpartum radical trachelectomy for IB1 squamous cell carcinoma of the cervix diagnosed in pregnancy. *Am J Obstet Gynecol* 2009;201:e8-e10. Available at:  
<http://www.ncbi.nlm.nih.gov/pubmed/19695559>.

325. Chan JK, Berek JS. Impact of the human papilloma vaccine on cervical cancer. *J Clin Oncol* 2007;25:2975-2982. Available at:  
<http://www.ncbi.nlm.nih.gov/pubmed/17617529>.